

Coronal Hypospadias: Meatal Advancement and Glanuloplasty or Tubularized Incised Plate Urethroplasty?

Osman Hakan Kocaman^{1*}, Tansel Günendi², Ali İhsan Anadolu², Mustafa Erman Dörterler¹ and Mehmet Emin Boleken¹

¹Harran University, Pediatric Surgery Department, Sanliurfa, Turkey

²Research and Teaching Hospital, Sanliurfa, Turkey

*Corresponding author: Osman Hakan Kocaman, Harran University, Pediatric Surgery Department, Sanliurfa/Turkey. Tel: +90 414 318 30 00; Fax: +90 414 318 31 90; E-mail: drhakankocaman@harran.edu.tr

Received date: 20 Mar 2017; Accepted date: 26 Sep 2017; Published date: 03 Sep 2017.

Citation: Kocaman OH, Günendi T, Anadolu AI, Dörterler ME, Boleken ME (2017) Coronal Hypospadias: Meatal Advancement and Glanuloplasty or Tubularized Incised Plate Urethroplasty? J Surg Open Access 3(5): doi <http://dx.doi.org/10.16966/2470-0991.157>

Copyright: © Kocaman OH, et al. This is an open-access article distributed under the terms of the Creative Commons Attribution License, which permits unrestricted use, distribution, and reproduction in any medium, provided the original author and source are credited.

Abstract

Introduction: Hypospadias is a congenital anomaly of urethra and penil foreskin. In this setting urethral meatus may place anywhere in penil shaft along corona to perineum. More than 300 surgical techniques for hypospadias repair have been described.

Method: In this study we aimed to present our cases operated with either Meatal Advancement and Glanuloplasty (MAGPI) or Tubularized Incised Plate Urethroplasty (TIPU) procedures for coronal hypospadias.

Results: Ninety six patients involved in the study, the urethral meatus were located coronally. The average age was 6.6. MAGPI was performed in 28 patients and TIPU was performed in 68 patients. Patients operated with MAGPI were carried in outpatient setting. Average hospital stay in patients operated with TIPU was 6,3 days. There were only complication in MAGPI procedure but in TIPU procedure 2 patients had fistula, 6 patients had meatal stenosis and 1 patient had glanular dehiscence. On follow up families were asked for cosmetic satisfaction, there were no difference between these procedures.

Conclusion: Many procedures were introduced for coronal hypospadias. MAGPI can be performed in selected cases because of low complication rate and short hospital stay.

Keywords: Hypospadias; MAGPI; TIPU

Introduction

Hypospadias is one of the most common anomalies of the male genitourinary system, with an incidence of 0.3% in male newborns [1]. In hypospadias, the urethral meatus is abnormally located on the ventral aspect of the penis. There are many classifications for hypospadias according to the location of the external meatus. Almost 65% of cases are classified as distal hypospadias [2].

The main goal in operating on this anomaly is to attain cosmetic and functional correction. Hypospadias repair should be performed with minimal complications and concern regarding the normal psychological development of the patient.

More than 300 surgical techniques for hypospadias repair have been described [3]. Which surgical technique should be used determined for each patient individually. The choice of surgical technique is often based on the surgeon's preference and morphology of the penis.

Material and Methods

We reviewed the medical files of patients who underwent coronal hypospadias repair between October 2013 and May 2016 in our clinic. Patients with chordee were excluded from the study. The operations were performed by 3 surgeons with the same surgical experience.

Meatal advancement and glanuloplasty (MAGPI) was performed in 28 (29.1%) patients and tubularized incised plate urethroplasty (TIPU) in 68 patients (70.9%). The choice of repair was made intra-operatively, depending on the position and mobility of the meatus and the quality of peri-urethral tissue. Our selection criteria were patients without ventral

chordee, thick, pliable parametarial skin, and a splayed type of glans with a deep groove. The patients who met these criteria underwent the MAGPI procedure. If patients met none of these criteria, then TIPU was selected.

In the MAGPI procedure, after placing a holding stitch at the apex of the glans with 4/0 Prolene (Ethicon, Somerville, NJ, USA), a circumferential incision is made around the corona proximal to the meatus. A vertical incision is made at the beginning of the urethral meatus and extended distally to the apex of the glans, a tag shaped piece of glanular tissue was removed and glans is closed horizontally with 6-0 polydioxanone (PDS; Ethicon) sutures. The glanuloplasty is made by reconfiguring the flattened glans into a conical shape by rotating the lateral wings around the midline proximal to the meatus. The glanular tissue is apposed with interrupted 6-0 PDS subcutaneous sutures taking bites from the urethra to avoid meatal regression (Figure 1); the epithelial edges may require one or two 6-0 PDS sutures.

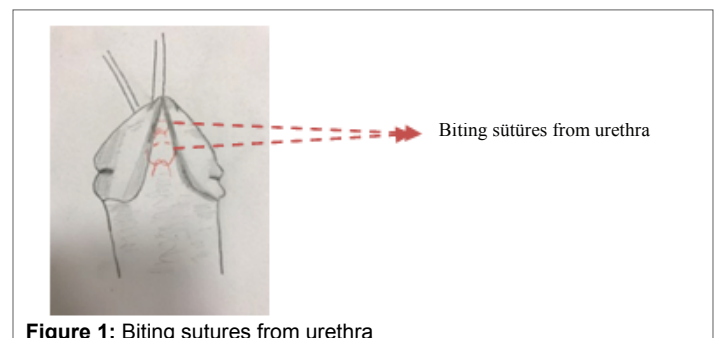


Figure 1: Biting sutures from urethra

For TIPU, a U-shaped skin incision is made surrounding the meatus, from the inferior margin of the meatus to the tip of the glans. The incised urethral plate is tubularized without tension over a 6/8Fr urethral catheter determined by the patient's age or the width of the urethra using non-interrupted 7-0 PDS (Ethicon) sutures. Dartos flap placed between neo-urethra and skin.

We recorded the duration of hospital stay, stenting time, cosmetic appearance, and complications.

Results

The average patient age was 6.6 years. All of the patients underwent circumcision after the hypospadias repair. The mean follow-up time was 9 months.

In the MAGPI group, only 1 (3.6%) patient had meatal stenosis requiring meatal dilatation (Table 1). The patients in this group had their catheters removed in 2 hours and the hospital stay was 6 hours postoperatively.

In the TIPU group, 2 (2.9%) patients had fistulas, 6 (8.8%) patients had meatal stenosis, and 1 (1.4%) patient had glanular dehiscence (Table 1). Only three patients needed a second operation. Meatal stenoses were managed with subsequent meatal dilatations with recovery. The average stenting time in this group was 6.2 days and the mean hospital stay was 3 days. In both groups, the patient's parents deemed the cosmetic appearance satisfactory. There were no significant differences between the two groups ($p > 0.05$, chi-square test).

In the MAGPI group duration of hospital stay and stenting time were shorter than TIPU which was statistically significant.

Discussion

Hypospadias is a common congenital anomaly in which the meatal orifice opens on the ventral aspect of the penis, instead of at the apex of the glans. The purpose of distal hypospadias repair should be functional and aesthetically satisfactory. In Bracka's study, normal appearance as well as normal function after hypospadias surgery was found to be important [4].

Many surgical techniques to repair anterior hypospadias have been reported, including MAGPI, the glans approximation procedure, and the Arab, Snodgrass (TIPU), and Mathieu techniques. The best surgical technique for hypospadias is still debated.

Factors influencing the choice of surgical technique include meatal location, presence or absence of chordee and distal urethral hypoplasia, configuration of the glans and experience of the surgeon [5-7].

Many reports have been published showing that the MAGPI procedure has complications and inadequate results [8,9]. The incidence of complications of MAGPI repair requiring a second operation ranges from 1.2% to 10% [2,7]. Poor patient selection, including a meatus located too far proximally and the presence of severe chordee, can lead to complications such as meatal regression and stenosis [2]. To avoid these complications, many authors have reported modifications to this procedure [10,11]. Taneli et al. suggested removal of a deep and tag-shaped glandular tissue piece during meatoplasty [12]. Samosa et al. reported that glans tissue was sutured with the ventral urethral wall [13].

Table 1: Complications in the MAGPI and TIPU groups

Complications	MAGPI (n=28)	TIPU (n=68)
Meatal stenosis	1	6
Urethral fistula	0	2
Glanular dehiscence	0	1
Cosmetic irregularity	0	0
Meatal regression	0	0

In 1994, Snodgrass [14] introduced the TIPU technique and it has become the most popular technique for distal hypospadias [15,16]. A recent meta-analysis by Pfistermuller et al. revealed low complication rates of meatal stenosis in 3.6%, urethral stricture in 1.3%, urethral fistula in 5.7%, and 4.5% re-operation rates in patients with distal hypospadias operated on using the TIPU procedure [17]. To prevent urethral fistula, which is the most common complication, flap on the neo-urethra is recommended [7].

In our series, the complication rate with the MAGPI procedure was low, which was probably due to the patient selection criteria (absence of ventral chordee, thick, pliable parameatal skin, and splayed type of glans with a deep groove). We also speculate that stitches biting the urethra while performing glanuloplasty hinder meatal regression, which is mostly seen after MAGPI operations.

Conclusion

Reviewing the previous literature we couldn't find any study comparing MAGPI versus TIPU in choosing patient criteria. The MAGPI and TIPU procedures are selected based on the surgeon's preference and morphology of the penis. MAGPI can be performed in selected cases because it has low complication rates and involves a short hospital stay.

Competing interests

The authors declare no competing financial or personal interests.

References

- Snodgrass WT (2012) Hypospadias. Campbell-Walsh Urology. 10th ed. Philadelphia: WB Saunders 3503-3536.
- Duckett JW, Snyder HM (1991) The MAGPI hypospadias repair in 1111 patients. *Ann Surg* 223: 620-626.
- Germiyanoğlu C, Nuhoğlu B, Ayyıldız A, Akgül KT (2006) Investigation of factors affecting result of distal hypospadias repair: comparison of two techniques. *Urology* 68: 182-185.
- Bracka A (1989) A long-term view of hypospadias. *Br J Plast Surg* 42: 251-255.
- Abu-Arefeh W, Chertin B, Zilberman M, Farkas I (1998) One stage repair of hypospadias: Experience with 856 cases. *Eur Urol* 34: 365-367.
- Duckett JW. Hypospadias. In Walsh PC, Retik AB, Stamey TA, Vaughan ED (eds) *Campbell's urology*, 6th edn. Saunders, Philadelphia, 1893-1919.
- Ghali AM, el-Malik EM, al-Malki T, Ibrahim AH (1999) One-stage hypospadias repair. Experience with 544 cases. *Eur Urol* 36: 436-442.
- Ozen HA, Whitaker RH (1987) Scope and limitations of the MAGPI hypospadias repair. *Br J Urol* 59: 81-83.
- Hastie KJ, Deshpande SS, Moisey CU (1989) Long term follow-up of the MAGPI operation for distal hypospadias. *Br J Urol* 63: 320-322.
- Arap S, Mitre AI, De Goes GM (1984) Modified meatal advancement and glanuloplasty repair of distal hypospadias. *J Urol* 131: 1140-1141.
- Baran CN, Sungur N, Kilinc H, Ozdemir R, Sensoz O (2002) T-Incision technique in distal hypospadias: a modification of meatal advancement and glanuloplasty. *Plast Reconstruct Surg* 109: 1018-1024.
- Taneli C, Genc A, Gunsar G, Sencan A, Arslan OA, et al. (1992) Modification of meatal advancement and glanuloplasty for correction distal hypospadias. *Scand J Urol Nephrol*. 38: 122-124.
- Somoza I, Liras J, Abuin AS, Mendez R, Tellado MG, et al. (2004) New Modern Magpi: meataladvancement and glanuloplasty clinical course. *Cir Pediatr: organo oficial de la Sociedad Espanola de Cirugia Pediatrica*. 17: 76-79.

14. Snodgrass W (1994) Tubularized incised plate urethroplasty for distal hypospadias. *J Urology* 151: 464-465.
15. Steven L, Cherian A, Yankovic F, Mathur A, Kulkarni M, et al. (2013) Current practice in paediatric hypospadias surgery: a specialist survey. *J Pediatr Urol* 9: 1126-1130.
16. Springer A, Krois W, Horcher E (2011) Trends in hypospadias surgery: results of a worldwide survey. *Eur Urol* 60:1184-1189.
17. Pfistermuller KL, McArdle AJ, Cuckow PM (2015) Meta-analysis of complication rates of the tubularized incised plate (TIP) repair. *J Pediatr Urol* 11: 54-59.