

A Case of an Endovascular Stent-Graft Infection Presenting as a Psoas Abscess

C Swain*¹ and S Ashley²

¹Institute of Naval Medicine, Royal Navy, UK

²Department of Vascular Surgery, Terence-Lewis Building, Derriford Hospital, Plymouth, Devon, PL6 8DH, UK

*Corresponding author: C Swain, 38 Clinton Avenue, Plymouth, PL4 7HA, England E-mail: cara@houseofswain.com; cara.swain104@mod.uk

Received date: 08 Sep 2015; Accepted date: 18 Sep 2015; Published date: 22 Sep 2015.

Citation: Swain C, Ashley S (2015) A Case of an Endovascular Stent-Graft Infection Presenting as a Psoas Abscess. J Surg Open Access 1(1): doi: <http://dx.doi.org/10.16966/2470-0991.104>

Copyright: © 2015 Swain C, et al. This is an open-access article distributed under the terms of the Creative Commons Attribution License, which permits unrestricted use, distribution, and reproduction in any medium, provided the original author and source are credited.

Abstract

Case report: A patient with history of endovascular aortic aneurysm repair and urosepsis presenting systemically unwell with hip pain, later diagnosed as a psoas abscess communicating with the aneurysmal sac.

Conclusion: There is a relationship between urosepsis and stent graft infection. Interventional procedures require careful planning and there is a role for prophylactic antibiotics. Surgeons should be vigilant to the possibility of late onset infection of variable presentation.

Keywords: Aortic aneurysm; Endovascular procedures; Stents; Vascular surgical procedures; Psoas abscess; Urinary tract infections

Introduction

Repair of abdominal aortic aneurysms using endovascular technique (EVAR), has become a popular alternative for vascular surgeons who believe the mortality and morbidity involved in elective open aneurysm repair would be too significant in a patient population with higher co morbidity.

Despite major technical improvements in stents/endografts since the procedure gained popularity, follow-up is essential due to potential late complications such as expansion of the aneurysm, perigraft aortic dilatation or infection, which require recognition and monitoring due the potential need for further interventions.

Case Report

A 76-year-old white male, who had undergone endovascular repair of a 6.6 cm infrarenal abdominal aortic aneurysm in 2011 and was known to have a Type II endoleak, presented 14 months later, cachetic and systemically unwell with severe pain in the left hip and compromised mobility. Significant past medical history included atrial fibrillation, chronic obstructive pulmonary disease and multiple urological interventions including six hospital admissions with urosepsis and urocalculi.

On examination; tender along the left hip joint line, with reduced range of moment and loss of internal rotation at the hip. He was afebrile, white cell count 16.7 with raised inflammatory markers (CRP 164), anaemic with haemoglobin 10.9, hypernatraemic and found to have primary hyperparathyroidism. A pelvic plain film demonstrated no fracture of the left hip, but computed tomography confirmed the presence of a psoas abscess, in close proximity to the aortic aneurysm sac.

A report of a biphasic abdomen-pelvis CT scan (Figure 1) stated: "... the aortic aneurysm sac has slightly decreased since the last scan... The known Type II endoleak is unchanged. However, the heterogenous psoas collection has increased in size, and there appears to be a communication between this and the (largely thrombosed) aneurysmal sac."

Management was intravenous antibiotics and radiologically-guided drainage of the psoas abscess; using Seldinger technique, a 10 French

pigtail catheter was inserted into the abscess via the left groin and free drainage of thick pus was established; a sample sent for microbiological analysis grew a mixture of coli forms. Serial blood cultures grew *Proteus mirabilis*, motile Gram-negative bacilli which is known to infect patients with complicated urinary tracts i.e. those with functional or anatomical abnormalities or long-term catheters. A hallmark of infection with *P. mirabilis* urinary stones [1], a significant feature of the patient's past medical history.

The patient was deemed unsuitable for further intervention due to frailty and lack of physiological reserve. Removal of the endovascular device (Lombard Aorfix) would have been challenging and would likely cause more harm to the patient. He was discharged home following a course of intravenous tazocin, and switched to oral augmentin to continue lifelong.

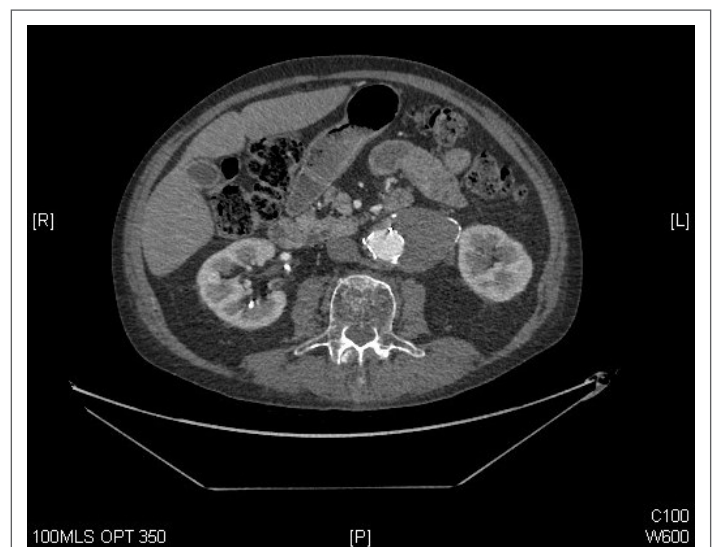


Figure 1: CT abdomen showing contrast within the aorta, the presence of the EVAR stent and the thrombosed aneurysm sac.

Discussion

The majority of surveillance following endovascular aortic aneurysm repair concentrates on the technical success of the procedure in reducing risk of aneurysm rupture including endoleak, device migration and monitoring of the neck for dilatation. Infection as a late complication of aortic aneurysm endovascular repair is relatively uncommon, with incidence of infected stents reported at 1-3% [2], but it is one of the most difficult management challenges faced by a vascular surgeon. The reported direct complications of infected stents include systemic bacteraemia, aortoenteric fistulae, para-aortic abscesses and psoas abscess. Additionally, associated mortality rates are high and morbidity includes risk of limb loss, gut ischaemia and renal failure.

Early infection occurs within three months and is typically caused by *Staphylococcus aureus*, graft contamination from patient skin flora during the procedure. The majority of graft infections occur after this time period, and are usually caused by *Staphylococcus epidermidis*, but also *E. coli*, *Pseudomonas*, *Proteus*, *Salmonella* and *Klebsiella* [2]. Secondary infection from a remote source most likely occurs due to haematogenous seeding, and is typically a late complication. Presentation has been reported as one-third chronic non-specific sepsis (malaise, weight loss), one-third acute sepsis and one-third with evidence of aortoenteric fistula [3]. Urological cause of infection is not uncommon; van der Berg et al. reported a stent-graft infection following septic complication of a kidney stone one year post-endovascular procedure [4].

Diagnosis is relatively straightforward with a history of fever, and evidence including elevated inflammatory markers and white cell count associated with fluid collections on imaging [5]. Subsequent management can be challenging and intervention must account for the nature of the presenting patient, but two options exist once diagnosis of an infected endovascular stent has been made – medical management using antibiotics reflecting the bacterium's susceptibility or surgical management where the infected graft is removed and surrounding tissue debrided before arterial reconstruction or extra-anatomic bypass is attempted [3]. In the case of aortic stents, explantation is complicated due to the nature of the devices themselves and the suprarenal fixation to the aortic wall with barbs or hooks.

If explantation is performed, tissue sent for microbiological analysis should be used to guide post-operative systemic antibiotic therapy; it was reported by Coselli et al. that in stent-graft infections, any replacement

polyester graft should be soaked in an antibiotic such as rifampicin to reduce likelihood of haematological colonisation due to bacteraemia [6].

Conclusion

This case report highlights a relationship between urosepsis and endovascular abdominal stent graft infection. Although the overall incidence of stent graft infection is relatively low, there are increasing numbers of endovascular procedures being performed, and vascular surgeons as well as other physicians need to be vigilant to the risk of infection and the variable late onset presentations.

When considering patients for endovascular procedures, prophylactic antibiotics could improve patient outcome in those with a history of urosepsis. Postponing the operation to ensure eradication would be of most benefit, but if not possible for clinical reasons, pre- and post-operative antibiotics should be administered, with use of antibiotic-soaked graft to prevent colonisation.

Once infection has been diagnosed, the mainstay of management is targeted antibiotic therapy of long-term duration and/or removal of the infected prosthesis where possible.

Conflict of Interest Statement: None

Acknowledgements: None

References

1. Struble K (2014) *Proteus* infections.
2. Van Zeeland MLP, van der Laan L (2011) Late Complications following Aortic Aneurysm Repair. In: Grundman RT eds. *Diagnosis, Screening and Treatment of Abdominal, Thoracoabdominal and Thoracic Aortic Aneurysms*. InTech 13: 211-226.
3. Laser A, Baker N, Rectenwald J, Eliason JL, Criado-Pallares E, et al. (2011) Graft infection after endovascular abdominal aortic aneurysm repair. *J Vasc Surg* 54: 58-63.
4. Van der Berg HR, Leijdekkers VJ, Vahl A (2006) Aortic stent-graft infection following septic complication of a kidney stone. *Cardiovasc Interv Radiol* 29: 443-445.
5. Hobbs SD, Kumar S, Gilling-Smith GL (2010) Epidemiology and diagnosis of endograft infection. *J Cardiovasc Surg* 51: 5-14.
6. Coselli JS, Green SY, LeMaire SA (2011) When Stent-Grafts Fail: extraction and open surgical repair of the thoracic aorta. *Tex Heart Inst J* 38: 658-660.