

Diaphyseal Fracture-Nonunion of Forearm Bone Treated by Compression Plating Aided with Autologous Bone Grafting - A Study Outcome

Kenan MA^{1*} and Habib HR²

¹Assistant Professor, Shaheed Sayed Nazrul Islam Medical College, Bangladesh

²Orthopedic Specialist and Medical Officer, Kishoreganj 250 Bed District Hospital, Bangladesh

*Corresponding author: Kenan MA, Assistant Professor, Shaheed Sayed Nazrul Islam Medical College, Bangladesh, E-mail: makenan.ortho@gmail.com

Received: 15 Dec, 2017 | Accepted: 09 Jan, 2018 | Published: 15 Jan, 2018

Citation: Kenan MA, Habib HR (2018) Diaphyseal Fracture-Nonunion of Forearm Bone Treated by Compression Plating Aided with Autologous Bone Grafting - A Study Outcome. *J Orthop Clin Stu Adv Res* 2(1): dx.doi.org/10.16966/2576-6449.106

Copyright: © 2018 Kenan MA, et al. This is an open-access article distributed under the terms of the Creative Commons Attribution License, which permits unrestricted use, distribution, and reproduction in any medium, provided the original author and source are credited.

Abstract

The forearm fulfills an important role in the integrated function of the upper extremity. Fracture non-union of forearm bone singly or both interfere with normal forearm function grossly. Non-union of the forearm bone cause dysfunction of forearm as they effect interosseus membrane, elbow and wrist and limit the rotational movement of forearm that is pronation and supination, stiffness of the elbow and wrist due to long term immobilization. But treatment of fracture - nonunion of forearm bone is still a therapeutic challenge and outcomes are moderate at best. This study was design and carried out to assess the outcome of treatment of fracture non-union of forearm bone by dynamic compression plating aided with autologous bone grafting from iliac crest. A prospective study was carried out from January' 2011 to December 2015 in where 20 cases of fracture-nonunion of forearm bone (radius n=8, ulna n=6, both n=6) were treated in government/private hospital situated in Kishoreganj of Bangladesh. Surgical procedure was performed following AO principle by dynamic compression plating aided with autologous bone grafting taken from iliac crest. Outcome was assessed by regular follow up, radiograph and functional outcome design by Anderson et al. Follow up time was 10 months to 24 months. Bony union was achieved within a median of 5 months. 18 patient achieved union within 4 month. According to the system of Anderson et al. 11 cases (55%) achieved excellent result. 4 cases (20%) had satisfactory and 5 cases (25%) had an unsatisfactory result. 1 patient developed infective non-union. This study showed that treatment of fracture - nonunion of forearm bone using technique of compression plating osteosynthesis aided by autologous bone grafting represent an effective treatment option of this challenging condition.

Keywords: Dyaphyseal fracture; Non-union; Radius, Ulna; Autologous bone graft

Introduction

Nonunion of the radius and ulnar shaft cause a severe anatomic and functional impairment related to disturbance of the interosseous membrane and dysfunction of the adjacent joints, elbow and wrist. These demanding nonunions require the surgical correction to restore the anatomy of the forearm and to improve function [1-6].

Compression plate-and-screw fixation of diaphyseal fractures of the radius and ulna in adults has been common practice since the late 1950s. Large series have shown this technique to be straightforward with a low complication rate. Controversies focused on bone grafting for acute fractures, the type and length of the plate and the risk of refracture after plate removal. Benefits of plate-and-screw fixation are the ability for anatomic and secure reconstruction allowing early motion. Complications of open reduction and internal fixation of forearm function are infection, malunion, non-union, nerve injury, compartment syndrome, bleeding, formation of a synostosis and limited function [7-11].

New techniques have been recently postulated for the treatment of forearm nonunions, including distraction-compression osteogenesis, locked plating, and locked intramedullary nailing. Even free flaps have been advocated as a means to restore anatomic length and ensure bony union [12-14].

In this study we applied the option of compression plating supported with autologous bone grafting for fracture non-union and evaluate the outcome radiologically and functional activities of affected extremities.

Methods

A prospective study was designed from January' 2011 to December 2015 in where 20 cases of fracture-nonunion of forearm bone (radius n=8, ulna n=6, both n=6) were treated in government/private hospital situated in Kishoreganj of Bangladesh (Table 1). Age of the patient was within 18 years to 58 years where male were 14 and female were 6 in number (Table 2). 12 case involved the right forearm and 8 patient involved in the left. No one of both forearms.

Mechanism of injury was in majority case road traffic accident (n=14) and then accidental fall (n=5). One patient had history of physical assault (Table 3). Two patients of diabetes mellitus (Controlled) in where one developed infection but improves after judicious use of antibiotic.

Isolated fracture of diaphyseal of the radius in 8 patient and in ulna 3 patient, Monteggia fracture in 3 patient and rest six patient involved both radius and ulna. 15 fracture were closed in nature and 5 fracture were open in of Gustilo type-I, Gustilo type-II A (Table 4).

Fortunately 19 patients did not involve with nerve injury. Only one patient with history of assault developed radial nerve palsy of neuropexia due to blunt trauma to arm which correct spontaneously within two months. Only in case of open fracture (n=5) four patient previously treated conservatively by recognized physician and majority of patient (n=16) were neglected and take treatment from Kabiraj (An ancient method like Tarzan medicine). All the patient were treated with open reduction and internal fixation with DCP aided with autologous bone grafting from iliac crest according to AO principle. Drain tube (where applied) were removed after 48 hours and patient were discharge from hospital after two weeks after removal of stitches. Follow up was done after 15 days and then every month's up to 10 to 24 months. Data were maintained according to follow up finding and result was recorded with radiological and clinical finding. Final outcome was designed with the method of Anderson et al. [7].

Results

Bony union was achieved within a median of 5 months of surgery. 18 patient of non-union healed within 4 months. 2 patient develop infection in where 1 cure with use of antibiotic therapy with unsatisfactory outcome. Another patient of infection with diabetes mellitus developed infected non-union with poor outcome left for further procedure. 1 patient with history of assault that develops radial nerve palsy improved satisfactorily within two months without any surgical intervention. Range of motion of wrist flexion was average of 68° (range 10 to 90), for wrist extension 65° (ranging from 10 to 90), for pronation 60° (ranging from 0 to 80), for supination 60° (ranging from 0 to 80). Movement of elbow joint average is 138° (ranging from 120 to 140).

According to the system of Anderson et al. (Table 5) 11 cases (55%) achieved excellent result. 4 cases (20%) had satisfactory and 5 cases (25%) had an unsatisfactory result. 1 patient developed infective non-union which was needed further intervention latter on (Figure 1).

Table 1: Fracture that involves the bone

Bone involve	No of case	Percentage
Radius	8	40%
Ulna	6	30%
Both	6	30%

Table 2: Gender distribution

	Number	Percentage
Male	14	70%
Female	6	30%

Table 3: Mechanism of injury

	No of case	Percentage
Road Traffic Accident	15	75%
Accidental Fall	4	20%
History of Assault	1	5%

Table 4: Type of fracture

Type of fracture	No of case	Percentage
Close Fracture	15	75%
Open (Gustilo type-I)	4	20%
Open (Gustilo type-II A)	1	5%

Table 5: Anderson et al criteria for assessment of functional outcome

Result	Union	Filexion and extension at wrist joint	Supination and pronation
Excellent	Present	<10° loss	<25% loss
Satisfactory	Present	<20° loss	<50% loss
Unsatisfactory	Present	<30° loss	<50% loss
Failure	Nonunion with or without loss of motion		

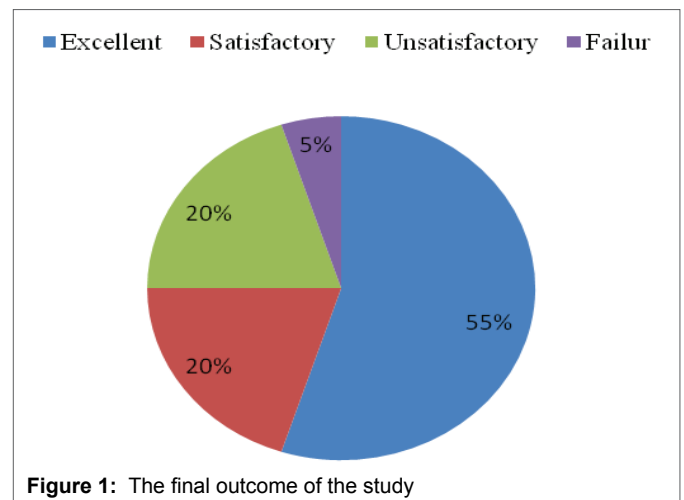


Figure 1: The final outcome of the study

Discussion

There are different options in treatment of diaphyseal fracture of forearm bone and compression plate and screw fixation is well established method. Union rate has been consistently high with good functional outcomes in up to 85%. Risk factors for development of a non-union are comminution, high energy fractures, open fractures and suboptimal surgical technique. Preservation of soft tissue attachments is important. There is no role for minimally invasive techniques as limited exposure will likely compromise the ability to obtain anatomic alignment. Stability of fixation is important in achieving early consolidation [7-11].

Result of treatment of diaphyseal fracture non-union in forearm bone treatment is good if principles of non-union surgery are followed. The principle are through debridement of avital tissues, removal of failed hardware, restoration of alignment, length, rotation, stable fixation using compression if possible, optimization of a bone forming environment including bone grafting if needed, allowing for early motion [15]. In this study the above principal were followed and the result was satisfactory according to study of Anderson et al. [7].

Infection is a common threat in all surgery and a big subject to overcome. In this study only 2 patients develop infection in where 1 in open fracture and other is in open fracture with diabetes mellitus which is compatible with the study of Fernando B.D et al. [16]. On the other hand fracture failed to unite in one patient out of 31 (3.2%) in there series which is better than our study 5%. There is no significant risk for ulna than radius to produce non-union in both bone fracture which is as like as the result of Peter Kloen et al. [15].

The result of this study is excellent in 55% (11 case) and satisfactory in 25% (4 case) which is also near to the result of Peter Kloen et al. [15] which was excellent in 62% and satisfactory in 17%. In their study no treatment failure was observed but in our study one patient failed to unite with poor outcome. In their study only one patient develop infection (3.2%) but in our study 2 patient develop infection (10%) which is double in our study.

Following AO technique with adequate debridement, eradication of infection and stable fixation using compression will lead to successful healing of the vast majority of forearm non-unions. Despite a very high chance of obtaining clinical and radiological healing of the non-union, patients should be informed that long-term functional outcome might be disappointing [17-18].

In the present study, the incidence of postoperative infection was much lower (2/20 patients). One case resulted in failure by developing chronic infected nonunions, while the other case was successfully managed by surgical debridement and antibiotic therapy, resulting in a healed union and a good functional long-term outcome.

Conclusion

In treatment of fracture of forearm bones treatment with dynamic compression plate is gold standard but in case of fracture non-union this is not always suffice. Autologous bone grafting specially from iliac crest is another standard method to enhance the union in fracture non union of forearm bones. Reconstruction of the anatomy of both forearm bones is of crucial importance in the management of the diaphyseal forearm nonunions. This study showed that treatment of fracture - nonunion of forearm bone using technique of compression plating osteosynthesis aided by autologous bone grafting represent an effective treatment option of this challenging condition.

References

1. Rochard MJ, Ruch DS, Aldridge JM 3rd (2007) Malunions and nonunions of the forearm. *Hand Clin* 23: 235-243.
2. Schemitsch EH, Richards RR (1992) The effects of malunion on functional outcome after plate fixation of fractures of both bones of the forearm in adults. *J Bone Joint Surg Am* 74: 1068-1078.
3. Hollister AM, Gellman H, Waters RL (1994) The relationship of the interosseous membrane to the axis of rotation of the forearm. *Clin Orthop Relat Res* 298: 272-276.
4. Skahen JR, Palmer AK, Werner FW, Fortino MD (1997) The interosseous membrane of the forearm: anatomy and function. *J Hand Surg Am* 22: 981-985.
5. Tarr RR, Garfinkel AI, Sarmiento A (1984) The effects of angular and rotational deformities of both bones of the forearm. *J Bone Joint Surg Am* 66: 65-70.
6. Jupiter JB, Ruedi T (1992) Intraoperative distraction in the treatment of complex nonunions of the radius. *J Hand Surg Am* 17: 416-422.
7. Anderson LD, Sisk D, Tooms RE, Park WI 3rd (1975) Compression-plate fixation in acute diaphyseal fractures of the radius and ulna. *J Bone Joint Surg Am* 3: 287-297.
8. Droll KP, Perna P, Potter J, Harniman E, Schemitsch EH, et al. (2007) Outcomes following plate fixation of fractures of both bones of the forearm in adults. *J Bone Joint Surg Am* 12: 2619-2624.
9. Mikek M, Vidmar G, Tonin M, Pavlovic V (2004) Fracture-related and implant-specific factors influencing treatment results of comminuted diaphyseal forearm fractures without bone grafting. *Arch Orthop Trauma Surg* 6: 393-400.
10. Ring D, Rhim R, Carpenter C, Jupiter JB (2005) Comminuted diaphyseal fractures of the radius and ulna: does bone grafting affect nonunion rate? *J Trauma* 2: 438-441.
11. Richard MJ, Ruch DS, Aldridge JM 3rd (2007) Malunions and nonunions of the forearm. *Hand Clin* 2: 235-243.
12. Orzechowski W, Morasiewicz L, Dragan S, Krawczyk A, Kulej M, et al. (2007) Treatment of non-union of the forearm using distraction-compression osteogenesis. *Ortop Traumatol Rehabil* 9: 357-365.
13. Ling HT, Kwan MK, Chua YP, Deepak AS, Ahmad TS (2006) Locking compression plate: a treatment option for diaphyseal nonunion of radius or ulna. *Med J Malaysia* 61: 8-12.
14. Krzykawski R, Król R, Kamiński A (2008) The results of locked intramedullary nailing for non-union of forearm bones. *Ortop Traumatol Rehabil* 10: 35-43.
15. Peter K, Wiggers JK, Buijze GA (2010) Treatment of diaphyseal non-unions of the ulna and radius. *Arch Orthop Trauma Surg* 130: 1439-1445.
16. Fernando BD, Flávio F, Hélio AF, Walter MA, Philip FS (2009) Outcome of diaphyseal forearm fracture-nonunions treated by autologous bone grafting and compression plating. *Ann Surg Innov Res* 3: 5.
17. Ring D, Rhim R, Carpenter C, Jupiter JB (2005) Comminuted diaphyseal fractures of the radius and ulna: does bone grafting affect nonunion rate? *J Trauma* 59: 438-441.
18. Baldy Dos Reis F, Faloppa F, Alvachian Fernandes HJ, Manna Albertoni W, Stahel PF (2009) Outcome of diaphyseal forearm fracture-nonunions treated by autologous bone grafting and compression plating. *Ann Surg Innov Res* 1: 5.