

# Extraction by Entrapment of a Thrombus attached to Transseptal Sheath during Atrial Fibrillation Ablation guided by Intracardiac Echocardiography

Doblado-Calatrava M<sup>1\*</sup>, Sánchez-Quintana D<sup>2</sup>, Cruz JM<sup>1</sup>, Vega CF<sup>1</sup>, García-Guerrero JJ<sup>1</sup> and Fernández de la Concha J<sup>1</sup>

<sup>1</sup>Department of Cardiology, Hospital Universitario Infanta Cristina, Badajoz, Spain

<sup>2</sup>Department of Anatomy and Cell Biology, Faculty of Medicine, University of Extremadura, Badajoz, Spain

\*Corresponding author: Doblado-Calatrava M, MD, Department of Cardiology, Hospital Universitario Infanta Cristina, Avenida de Elvas s/n, 06080 Badajoz, Spain, Tel: +34699624199; Fax: 924275830; E-mail: [dobladoombe@hotmail.com](mailto:dobladoombe@hotmail.com)

Received date: 06 Nov 2015; Accepted date: 24 Nov 2015; Published date: 30 Nov 2015.

Citation: Doblado-Calatrava M, Sánchez-Quintana D, Cruz JM, Vega CF, García-Guerrero JJ, et al. (2015) Extraction by Entrapment of a Thrombus attached to Transseptal Sheath during Atrial Fibrillation Ablation guided by Intracardiac Echocardiography. J Hear Health 1 (4): doi <http://dx.doi.org/10.16966/2379-769X.117>

Copyright: © 2015 Doblado-Calatrava M, et al. This is an open-access article distributed under the terms of the Creative Commons Attribution License, which permits unrestricted use, distribution, and reproduction in any medium, provided the original author and source are credited.

## Abstract

A middle-aged woman with symptomatic paroxysmal atrial fibrillation refractory to pharmacological treatment was referred for catheter ablation. During the procedure, a left atrial thrombus was visualized within the left atrium attached to a transseptal sheath. In our case we used a different approach for extraction of thrombus.

**Keywords:** Catheter ablation; Intracardiac echocardiography; Transseptal catheterization; Intracardiac thrombus; Atrial fibrillation

**Abbreviations:** ACT: Activated Clotting Time; AF: Atrial Fibrillation; ICE: Intracardiac Echocardiography

## Introduction

Cardioembolic events are one of the most serious complications during atrial fibrillation (AF) ablation. According to studies with intracardiac echocardiography, the incidence of thrombus associated with sheaths or catheters is about 9-10% in left atrium ablation procedures [1], and up to 2% of systemic embolization has been observed [2]. Several strategies have been published for extraction of thrombus including direct withdrawal of the sheath [3] or vigorous aspiration of the thrombus [1]. We report a case in which we used a different approach for extraction of a thrombus attached to the distal tip of a sheath placed in the left atrium.

## Case Report

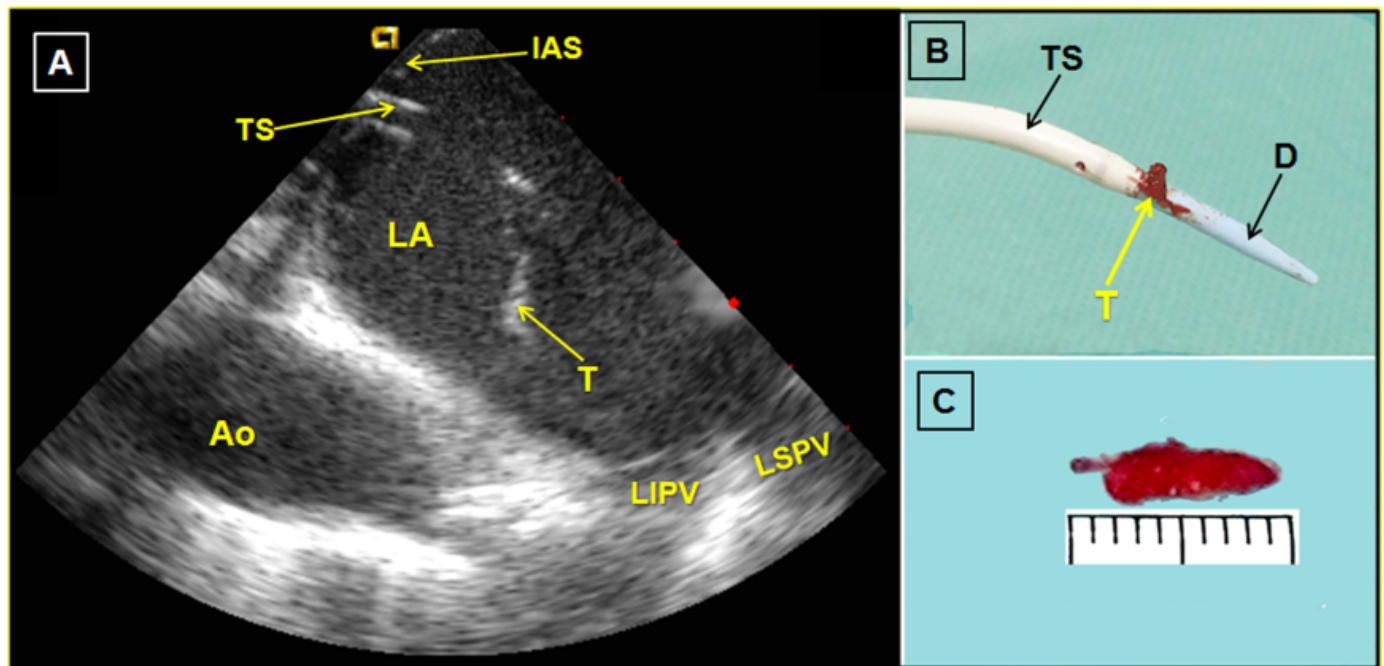
A 41-year-old woman smoker with symptomatic paroxysmal AF refractory to beta-blockers and flecainide was referred to our institution for pulmonary vein ablation. She was not taking anticoagulants. Transthoracic echocardiography showed normal ventricles and valves and a moderately enlarged left atrium (45 × 52 mm). A preprocedural transesophageal echocardiogram confirmed the absence of intraatrial thrombus.

Prior to the trans-septal puncture a bolus of 3000 IU of heparin was administered. A first transseptal puncture was performed without difficulty guided by ICE (AcuNav catheter, Siemens Medical Solutions, Mountain View, CA, USA). An 8.5 F transseptal sheath (SL1, St. Jude Medical, St. Paul, MN, USA) and a BRK1 puncture needle (St. Jude Medical) were used. Immediately after puncture, a bolus of 5000 U of heparin was administered. The sheath was continuously flushed with heparinized saline (2 units/mL) at a rate of 30 mL/h. Approximately 5 minutes later and before performing a second transseptal puncture, a mobile thrombus attached to the distal tip of the sheath (0.9 cm long × 0.3 cm wide) was observed (Figure A; Supplementary Video). An additional 6000 U of heparin was administered obtaining an activated clotting time (ACT) of 288 s. Given the persistence of the thrombus after waiting 20 minutes, it

was attempted to aspirate it vigorously through the sheath but this was not effective. Since the thrombus was strongly attached to the distal tip of the sheath, it was decided to advance the dilator to trap the thrombus between the dilator and the sheath. Dilator size was similar to the width of the thrombus. This manoeuvre involves some risk of thrombus embolization and was performed under continuous monitoring with ICE with special attention to cross the distal portion of the sheath. The dilator and sheath were then withdrawn as a single unit allowing complete extraction of the thrombus outside the patient (Figures B and C). After the four pulmonary veins were successfully isolated under intense heparinization and ACT values above 300. The intervention was completed without incidents and the patient did not experience any cardioembolic complication in the periprocedure.

## Discussion

Thrombus formation during left atrial ablation procedures is relatively common and the use of ICE plays a very important role in its early detection, which is essential to adopt therapeutic measures. Possible causes of thrombus formation include the presence of spontaneous echo contrast; prothrombosis induced by the sheath or catheter itself, delayed or insufficient heparinization, and vascular injury [4]. Several strategies have been published for extraction of thrombus. One is direct aspiration through the sheath [1] but in our case it was not effective, probably because the thrombus was strongly attached to the distal end of the sheath. Another technique is simple withdrawal of the sheath and thrombus as a single unit. Ren et al. [3] used this technique for the extraction of 30 thrombus. Of these, 27 were removed successfully to the right atrium and 2 remained trapped in the interatrial septum. It should be noted that only 8 of the 30 thrombi were extracted outside the patient and the rest presumably remained at the level of the venous system, suggesting a high percentage of dislocation during the maneuver of simple withdrawal. Finally, some cases of intraatrial thrombolysis have also been reported [5].



**Figure 1:** A-Intracardiac echocardiography image demonstrated a thrombus (T) attached at the transseptal sheath (TS) in the left atrium (LA). IAS=Interatrial septum. Ao=Descending aorta. LIPV=Left inferior pulmonary vein. LSPV=Left superior pulmonary vein. B- Image showing thrombus (T) between the transseptal sheath (TS) and dilator (D). C- Caliper thrombus size in millimeters

In our case, after the impossibility of aspirating the thrombus, we considered simple withdrawal of the sheath and thrombus. However, we thought there was a high risk of thrombus dislocation during this maneuver either in its passage through the interatrial septum or through the lower venous system. Thrombolysis was ruled out due to the high risk of bleeding and thrombus fragmentation and embolism. Finally, we opted to advance the dilator through the sheath to trap the thrombus between the sheath and the dilator thus reducing the risk of thrombus dislocation during the withdrawal maneuver. To our knowledge, this is the first reported case using this modality of extraction.

## Conclusion

Thrombus entrapment attached to transseptal sheath during atrial fibrillation ablation guided by intracardiac echocardiography can be an alternative when other thrombus extraction techniques have not been successful.

## Acknowledgement

This project was funded in part by Grant TIN2012-37546-C03-02 from the Ministerio de Economía y Competitividad (Spain).

## References

1. Maleki K, Mohammadi R, Hart D, Cotiga D, Farhat N, et al. (2005) Intracardiac ultrasound detection of thrombus on transseptal sheath: incidence, treatment, and prevention. *J Cardiovasc Electrophysiol* 16: 561-565.
2. Kok LC, Mangrum JM, Haines DE, Mounsey JP (2002) Cerebrovascular complication associated with pulmonary vein ablation. *J Cardiovasc Electrophysiol* 13: 764-767.
3. Ren JF, Marchlinski FE, Callans DJ (2004) Left atrial thrombus associated with ablation for atrial fibrillation: identification with intracardiac echocardiography. *J Am Coll Cardiol* 43: 1861-1867.
4. Dorbala S, Cohen AJ, Hutchinson LA, Menchavez-Tan E, Steinberg JS (1998) Does radiofrequency ablation induce a prethrombotic state? Analysis of coagulation system activation and comparison to electrophysiologic study. *J Cardiovasc Electrophysiol* 9: 1152-1160.
5. Tomasi C, Placci A, Giannotti F, Margheri M (2011) Intra-atrial thrombolysis of left atrial thrombus guided by intracardiac echocardiography during catheter ablation of atrial fibrillation. *Heart Rhythm* 8: 1773-1776.