

# Phrenic Nerve Block used to Treat Persistent Hiccups Provoked by a Nissen's Fundoplication

Prieto-Puga T<sup>1,\*</sup>, Moreno J<sup>1</sup>, Guadalix JI<sup>2</sup>, Fernández I<sup>1</sup>, Rodríguez-Cañete A<sup>1</sup>, Titos A<sup>1</sup>, López B<sup>1</sup>, Bondía JA<sup>1</sup> and Santoyo J<sup>1</sup>

<sup>1</sup>Esophagogastric unit, General Surgery, Gastroenterology and Transplant, Regional Hospital Universitario Carlos Haya, Spain

<sup>2</sup>Anesthesiology Service, Regional Hospital Universitario Carlos Haya, Spain

\*Corresponding author: Prieto-Puga T, Hepatobiliopancreatica and Transplant Unit, Regional Hospital Universitario Carlos Haya, Spain, E-mail: [prietopugaarjona.tatiana@gmail.com](mailto:prietopugaarjona.tatiana@gmail.com)

Received date: 26 Nov 2015; Accepted date: 13 Jan 2016; Published date: 18 Jan 2016.

Citation: Prieto-Puga T, Moreno J, Guadalix JI, Fernández I, Rodríguez-Cañete A, et al. (2016) Phrenic Nerve Block used to Treat Persistent Hiccups Provoked by a Nissen's Fundoplication. J Gastric Disord Ther 2 (1): <http://dx.doi.org/10.16966/2381-8689.111>

Copyright: © 2016 Prieto-Puga T, et al. This is an open-access article distributed under the terms of the Creative Commons Attribution License, which permits unrestricted use, distribution, and reproduction in any medium, provided the original author and source are credited.

## Abstract

Hiccups are produced by contraction of the diaphragm and the accessory inspiratory muscles resulting in abrupt closure of the glottis accompanied by a characteristic sound. It is a normal, self-limited phenomenon, but in certain cases it can become chronic and lead to serious deterioration in the quality of life. The mechanism is not fully understood; various treatments to control persistent hiccups have been described with varying degrees of success.

We present a case of persistent hiccups that did not respond to pharmacological treatment. A broad range of causes of acute hiccups have been identified; the presence of intractable hiccups can be indicative of a more serious pathology. Persistent hiccups can produce significant morbidity. Several pharmacological and non-pharmacological treatment modalities exist but there is little scientific evidence of their safety and effectiveness. Phrenic nerve block is one such treatment for persistent hiccups. This block is used in situations in which a central etiology has been ruled out and the hiccups do not respond to other pharmaceuticals or electrical stimulation of the phrenic nerve.

## Introduction

Hiccups are produced by contraction of the diaphragm and the accessory inspiratory muscles resulting in abrupt closure of the glottis accompanied by a characteristic sound [1-6]. It is a normal, self-limited phenomenon, but in certain cases it can become chronic and lead to serious deterioration in the quality of life [1-4]. The mechanism is not fully understood; the literature discusses a stimulation of the hiccup reflex arc, composed of the phrenic, vagus and thoracic sympathetic nerves [1,3,4]. Etiology of hiccups includes pathology in the central nervous system, abdomen, or thorax and general anesthesia [1]. Sometimes no cause is found and it is labeled as idiopathic [4]. Various treatments seeking to control persistent hiccups have been described with varying degrees of success [4,6].

## Case Report

We present a case of a 45-year old woman with no significant medical history who underwent a laparoscopic Nissen's fundoplication to treat a large hiatal hernia with gastro-oesophageal reflux. Six months after surgery she developed persistent hiccups of such an intensity and frequency that it affected her quality of life; treatment with PPIs and prokinetics was begun and diagnostic tests were conducted - the barium transit test, manometry and pH-metry - results were all normal. Due to the persistence of clinical symptoms an abdominal CT scan and endoscopy were also done and they were also normal. Baclofen was added to the treatment regimen. Symptoms persisted and CT thorax was done which was normal. An electrophysiology study was carried out in which the size of the left phrenic nerve was observed to be smaller than the right. Therefore the decision was taken to perform an anaesthetic block of the left phrenic nerve (Figure 1). The nerve was first blocked with lidocaine 2%, which produced a transient symptomatic improvement. Therefore a second infiltration was performed with a longer-lasting anaesthetic, levobupivacaine, resulting in complete resolution of hiccups. The same

procedure was repeated one week later - a perfusion of levobupivacaine was administered for 24 h by means of a perineural catheter placed with the aid of ultrasound and electrical stimulation. After 48 h, hiccups reappeared with episodes occurring once per hour, so it was decided to repeat the perfusion for another 24 h and three days after withdrawing the catheter the patient was asymptomatic. An elevation of the left hemi diaphragm was observed in the chest X-ray due to the left phrenic nerve paralysis but there were no apparent respiratory repercussions (Figure 2). Two years after the procedure described above the patient is still asymptomatic.

Acute hiccups (less than 48 h) are normally due to benign causes such as gastric distension, rapid ingestion, and temperature changes in the

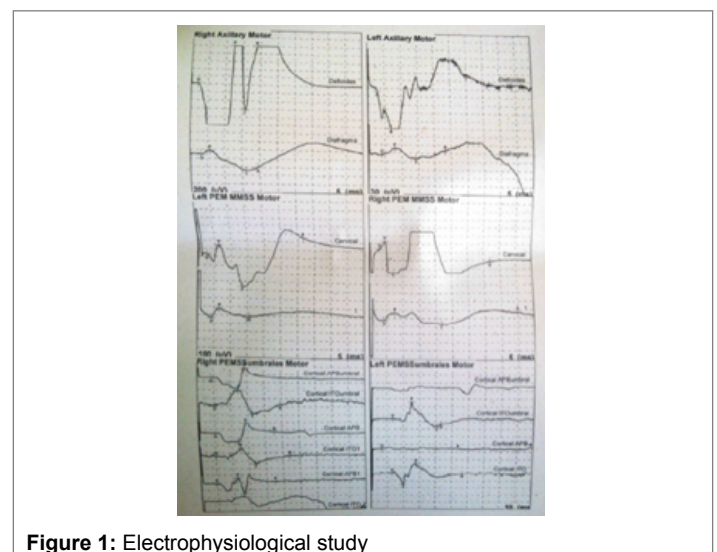
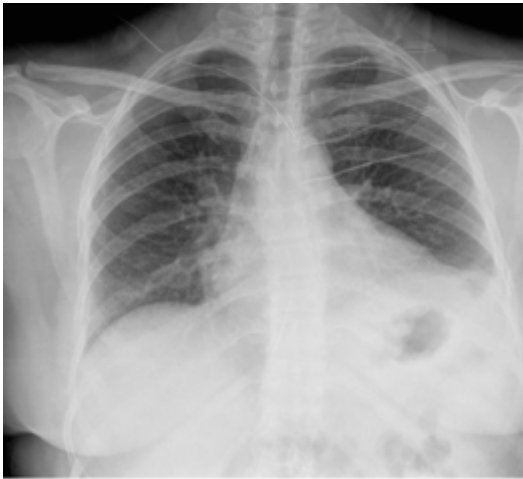


Figure 1: Electrophysiological study



**Figure 2:** Chest X-rays during the months after the anaesthetic block of the phrenic nerve

stomach, excessive consumption of tobacco or alcohol and emotional stress. Hiccups which last for more than 48 h are classified as persistent, and when they last for more than 2 months they are considered to be intractable and termed singultus [3,6].

A broad range of causes of acute hiccups have been identified, including gastric distension, consumption of carbonated alcoholic and non-alcoholic drinks, hot or cold drinks, anxiety and stress. The presence of intractable hiccups can be indicative of a more serious pathology; more than 100 causes of persistent and intractable hiccups have been observed, examples include damage to the central nervous system, irritation of the diaphragm, irritation of the vagus nerve, drugs, metabolic, psychogenic, surgical, infectious or idiopathic causes, and also medicinal products such as benzodiazepines and corticosteroids [6].

Persistent hiccups can produce significant morbidity such as the incapacity to eat, loss of weight, tiredness, insomnia, cardiac arrhythmias, emotional disorders such as anxiety, depression and even suicide [1,3,4,6].

Several pharmacological and non-pharmacological treatment modalities exist [1,6], but there is little scientific evidence available regarding their safety and efficacy [6]. Conventional treatments include the use of CNS depressants (bromides, ether and magnesium sulphate) and stimulants (ephedrine), dopamine blockers (chlorpromazine, metoclopramide, haloperidol and droperidol), antiepileptics (valproic acid, carbamazepine), calcium channel blockers (nifedipine), and anticholinergic medicines (atropine) [1,6]. The most frequently used are chlorpromazine, metoclopramide, baclofen and valproic acid [1].

Other treatment modalities include acupuncture [4], anaesthetic blocking of the glossopharyngeal nerve [5] and the phrenic nerve [7,8], and general anaesthesia with relaxation and ventilation with a face-mask [2].

Treatment of persistent hiccups is one indication of phrenic nerve block. This block is used in situations in which a central etiology has been ruled out and the hiccups do not respond to other pharmaceuticals or electrical stimulation of the phrenic nerve [9].

## Summary

It is technically preferable to perform the phrenic nerve block immediately cranial to the clavicle. The site of the block is crucial, therefore, the use of ultrasound and electrical stimulation is recommended to aid placement. The block involves a partial, unilateral diaphragmatic paralysis with negligible impairment of the vital functional capacity in patients with no pulmonary pathologies; however, patients with an advanced restrictive pulmonary disease or deterioration of the contra lateral mobility of the diaphragm can experience significant respiratory symptoms [9].

In summary, phrenic nerve block is an effective technique in the treatment of persistent hiccups that do not respond to conventional treatments.

## Conflict of Interest

The authors report no conflicts of interests.

## References

1. Alonso-Navarro H, Rubio L, Jiménez-Jiménez FJ (2007) Refractory Hiccups: Successful treatment with gabapentin. *Clin Neuropharmacol* 20: 186-187.
2. Lierz P, Felleiter P (2002) Anesthesia as therapy for persistent hiccups. *Anesth Analg* 95: 494-495.
3. Martínez Rey C, Villamil Cajoto I (2007) [Hiccup: review of 24 cases]. *Rev Méd Chil* 135: 1132-1138.
4. Schuepfer GK, Poelaert JI, Konrad C (2003) General Anesthesia or phrenic nerve block for treatment of chronic hiccups? *Anesth Analg* 96: 907-916.
5. Okuda Y, Kamishima K, Arai T, Asai T (2008) Combined use of ultrasound and nerve stimulation for phrenic nerve block. *Can J Anesth* 55: 195-196.
6. Calvo E, Fernández-La Torre F, Brugarolas A (2002) Cervical phrenic nerve block for intractable hiccups in cancer patients. *J Natl Cancer Inst* 94: 1175-1176.
7. Michálek P, Kautznerová D (2002) Combined use of ultrasonography and neurostimulation for therapeutic phrenic nerve block. *Reg Anesth Pain Med* 27: 306-308.
8. Canella C, Demondion X, Delebarre A, Moraux A, Cotten H, et al. (2010) Anatomical study of phrenic nerve using ultrasound. *Eur Radiol* 20: 659-665.
9. Moretto EN, Wee B, Wiffen PJ, Murchinson AG (2013) Interventions for treating persistent and intractable hiccups in adults. *Cochrane Database Syst Rev* 1: CD008768.