Sci Forschen
Open HUB for Scientific Research

Journal of Clinical Case Studies
ISSN 2471-4925 | Open Access

CASE REPORT

Volume 7 - Issue 3

Type 1 Diabetes Mellitus and Peripheral Nerve Injury Occurring After PD-1 Treatment: A Case Report and Analysis

Yuan Tian, Tieli Li, Haixuan Ding, Xinlan Zhao, Juan Luo, Kai Chen, Zhuo Tang, Lingyun Huang, Langbo Li, and Li Yang*

Department of Endocrinology, First Affiliated Hospital of Hunan Normal University (Hunan Provincial People's Hospital), China

***Corresponding authors:** Li Yang, Department of Endocrinology, First Affiliated Hospital of Hunan Normal University (Hunan Provincial People's Hospital), China; Email: 2244652700@qq.com

Received: 01 Aug, 2022 | **Accepted:** 20 Aug, 2022 | **Published:** 10 Sep, 2022

Citation: Tian Y, Li T, Ding H, Zhao X, Luo J, et al. (2022) Type 1 Diabetes Mellitus and Peripheral Nerve Injury Occurring After PD-1 Treatment: A Case Report and Analysis. J Clin Case Stu 7(3): dx.doi.org/10.16966/2471-4925.258

Abstract

Objective: To raise the clinicians' awareness of the rare adverse event of Immune Checkpoint Inhibitor (ICPis)-associated diabetes mellitus and peripheral nerve injury.

Methods: We report a case of ICPis-associated diabetes and peripheral nerve injury caused by treatment with pablizumab in a 60-year-old male with lung cancer.

Results: We describe a 60-year-old male who presented with "three more and one less" diabetic symptoms and severe numbness in the extremities after treatment with pabrolizumab. Based on the patient's clinical symptoms, ancillary tests and corresponding follow-up findings, the patient was finally diagnosed with ICPis-associated type 1 diabetes and ICPis-associated peripheral nerve injury. The patient had poor compliance and was not given insulin glucose-lowering therapy at the beginning of the disease, and now the pancreatic islet function was severely impaired, the glycemic control was poor, and the numbness of the extremities did not improve significantly, which seriously affected the quality of life of the patient.

Conclusion: ICPis-related diabetes mellitus and peripheral nerve injury is a relatively rare immune-related adverse reaction, which progresses rapidly and is more harmful, and therefore, should be taken seriously by doctors and patients in clinical work.

Keywords: Immune checkpoint inhibitors; Immune-related adverse reactions; Programmed death receptor 1; Type 1 diabetes mellitus; Peripheral nerve injury

Introduction

The use of Immune Checkpoint Inhibitors (ICPis) has now become an effective treatment for many malignancies. Two major classes of ICPis with well-defined anti-tumor efficacy are anti-CTLA-4 antibodies and anti-PD-1/PD-L1 antibodies, both of which have been approved by the FDA for clinical use. Immune checkpoints are molecules on the surface of immune cells involved in regulating immune responses, and ICPis are monoclonal antibodies that target certain immune checkpoints. Interference with this mechanism causes Immune-Related Adverse Events (irAEs) most commonly leading to endocrine disease. Even though some endocrine disorders caused by ICPis are remitted by monitoring and symptom control alone, most endocrine disorders, such as central adrenal insufficiency, primary hypothyroidism or insulin-deficient diabetes mellitus, require lifelong appropriate hormone replacement [1].

Diabetes mellitus is one of the less common endocrine irAEs treated with ICPis, mainly seen with PD-1 inhibitors [2]. 76% of patients with ICPis-associated diabetes mellitus develop DKA, of which 38.9% are severe, 20.4% are moderate, and 11.1% are mild [3]. Patients with ICPis-associated diabetes mellitus have an age of onset compared to regular T1DM [4] as older, faster and significant islet impairment, significantly reduced islet release function after onset, and a greater proportion of patients exhibiting fulminant T1DM with a smaller proportion of autoantibody positivity. The pathogenesis leading to ICPis-associated diabetes is unclear and may be due to the activation of a series of T-lymphocyte-mediated autoimmune responses in patients treated with ICPis, leading to the destruction and functional failure of selective islet B cells and progressive underproduction of insulin in vivo, leading to diabetes. Adverse neurological reactions caused by ICPis are rare, with an incidence of no more than 3% [5]. Peripheral neuropathy is the most common ICI-related neurological adverse reaction, with an incidence of no more than 1% [6,7], accounting for 1/3-2/3 of all ICPis-related neurological adverse reactions. In this paper, we analyzed the clinical characteristics of a case of ICPis-related diabetes mellitus in a patient with lung cancer, who was admitted to our endocrinology department after receiving pabrolizumab treatment, hoping to draw clinical attention of physicians and patients at work.

Case Material

Patient, male, 60 years old, underwent lung cancer surgery at an outside hospital in September 2020 and received a total of 4 cycles (22 days per cycle) of methylprednisolone combined with pabrolizumab after surgery

On February 22, 2021, he was hospitalized in Hunan Cancer Hospital for review of "post-lung cancer surgery". During the hospitalization, he developed symptoms of excessive drinking, polyuria, dry mouth and numbness of limbs, and measured fasting blood sugar of 18.09 mmol/L. He was discharged without targeted treatment

On March 4, 2021, the patient went to Xiangya Hospital with symptoms of polydipsia, polyuria, dry mouth and numbness of limbs, and was diagnosed as "type 1 diabetes mellitus (immunotherapy related) diabetic ketoacidosis" treated with "acarbose, ligliptin and mendon insulin", and thereafter, was discharged from the hospital

On March 19, 2021, he was admitted to our hospital with "polyuria, dry mouth, excessive drinking, and numbness in the extremities for 2 months". He was diagnosed with "drug-induced type 1 diabetes mellitus, drug-induced nerve damage, diabetic peripheral vasculopathy", and was given 7, 8, and 8 U of menthol insulin morning, noon, and night, and 16 U of recombinant glargine insulin subcutaneously at bedtime, as well as symptomatic treatment such as nerve nutrition

Body temperature: 36.6°C, pulse: 120 beats/min, respiration: 20 breaths/min, blood pressure: 134/89Hg, normal development, good nutrition, normal face, clear mind, fair spirit, large erythematous skin rash with white skin desquamation, and no palpable enlargement of superficial lymph nodes. Laboratory tests after admission (Table 1) indicated that the patient had elevated blood glucose, significantly decreased C-peptide level, and negative insulin autoantibodies. The electrocardiogram was normal. Subsequently, the patient came to our hospital for monthly inpatient review, which revealed that C-peptide decreased significantly (Figure 1) and was not reversed.

Table 1: Laboratory results on admission.

	Unit	Result	Reference interval
Blood			
glucose	mmol/L	19.5	3.89-6.11
total protein	g/L	54.3	60-85
albumin	g/L	33.16	35-55
Total serum cholesterol	mmol/L	5.25	3.4-5.2
low density lipoprotein	mmol/L	3.86	0-3.64
Neutrophil percentage	%	76	40-70
FT3	pmol/L	3.66	2.43-6.01
TSH	uIU/mL	0.46	0.35-4.94
FH4	pmol/L	13.47	9.01-19.05
Urine			
glucose		4+	negative
ketone body		2+	negative
N-Acetyl-B-D-aminoglucosidase	ng/L	57.9	0.3-14.6
Diabetes			
C-peptide	ng/L	0.03	0.78-5.19
Glutamic Acid DecarboxylaseAntibody (GADA)	IU/mL	2.97	0-10
Insulin autoantibodies (IAA)	COI	0.07	0-0.9
Tyrosine phosphatase (IA 2A)	IU/mL	<0.70	0-10
Islet cell antibodies	COI	0.07	0-0.9

Note: **FT3:** serum free triiodothyronine; **TSH:** serum thyroid stimulating hormone; **FT4:** serum free thyroid hormone.

Discussion

Previous studies have reported [8] that T1DM is an adverse effect of PD-1 monoclonal antibody. The median time of onset from the start of treatment with ICPis to elevated blood glucose levels varied from 13 to 504 days, with a greater chance of occurrence within the first 6 months [9,10]. The case reported herein developed T1DM after 3 months of treatment with PD-1 antibodies with an acute onset and a tendency to ketosis. Unlike common T1DM, the patient had a high age of onset and was insulin autoantibody negative, with a markedly lower C-P at onset. C-P levels were subsequently reviewed monthly in our hospital, where C-P dropped to undetectable levels and showed no signs of elevation (Figure 1), and indicating rapid and irreversible islet failure. The patient was not diagnosed and began insulin therapy in time when the elevated blood glucose was first detected, and was not taken seriously until the symptoms worsened. Therefore, the patient's blood glucose needs to be monitored when starting ICPis medication. Since ICPis-associated diabetes is usually permanent and damages islet function rapidly, glycated hemoglobin needs to be monitored every 3 months after treatment with insulin, islet function needs to be evaluated monthly, and insulin autoantibodies need to be tested annually to adjust insulin dose in time to avoid life-threatening complications such as DKA.

The special point of this paper is that the patient's symptoms of numbness in the extremities were prominent and appeared at an early stage. Compared with primary diabetic peripheral neuropathy, the patient's symptoms of numbness in the extremities did not improve significantly after insulin treatment. The patient's EMG results showed that the nerve motor conduction velocity was slowing down (Figure 2), and this symptom seriously affected the patient's quality of life. The patient denied and past and family histories of diabetes mellitus, the symptoms of numbness in the extremities appeared early, and the patient's symptoms did not improve significantly after the release of glucotoxicity. After being treated with insulin, glucotoxicity was relieved and the rapid deterioration of peripheral nerve injury was slowed down, but the efficacy was poorer than that of primary diabetic peripheral neuropathy, and the differences between the two were as follows (Table 2) [11,12-14].

A review of the literature [15] shows that immune-related adverse reactions involve almost all systems, with neurological adverse

Table 2: Differentiation of ICPis related peripheral neuropathy from primary diabetic peripheral neuropathy.

	ICPis-related peripheral neuropathy	Diabetic peripheral neuropathy
Main pathogenesis	Peripheral nerve demyelination, where the body loses immune tolerance to myelin or axonal antigens of peripheral nerves	Hyperglycemia causes edema, degeneration and necrosis of nerve cells, resulting in demyelination of nerve fibers and axonal degeneration
Time of onset	Any time during or after ICPis treatment	T2DM is diagnosed or 5 years after T1DM diagnosis
Mode of onset	Mostly acute or subacute	Slower, early symptoms are not obvious
Electrophysiological examination	Demyelinating changes, including prolonged F-wave latency, reduced peripheral nerve conduction velocity and conduction block	The earliest abnormality is a prolongation of the H-reflex latency, followed by a decrease in the wave amplitude of the nerve potential and, as the disease worsens, a slowing of conduction velocity may occur. The slowing of conduction velocity is due to metabolic factors that cause damage to the axon of fast-conducting fibers and does not reach the severity of demyelinating lesions
Clinical manifestations	Acute sensory-motor disorder with reduced nerve reflexes	Early on, painful sensations appear, and as the disease worsens, it manifests as deep sensory disturbances, manifesting as sensory ataxia such as unsteadiness in walking
Progression process	Rapid progression, obvious symptoms	Progression is mostly slow, those with a disease course of 10 years or more are prone to obvious clinical symptoms
Treatment	First-line drugs: glucocorticoids Second-line drugs: immunoglobulins, plasma exchange	Glucose control, nerve repair, circulation improvement and treatment for the pathogenesis of neuropathy

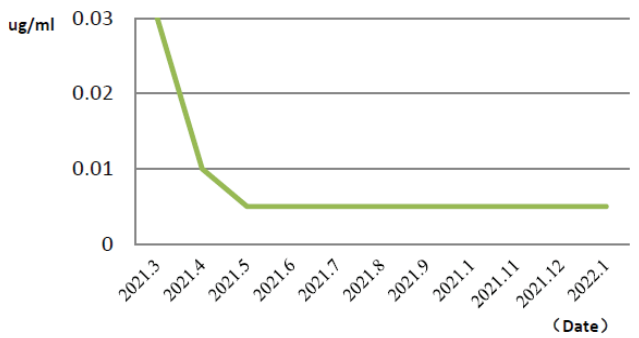

Figure 1: March 2021-January 2022 C-peptide release level folding chart.

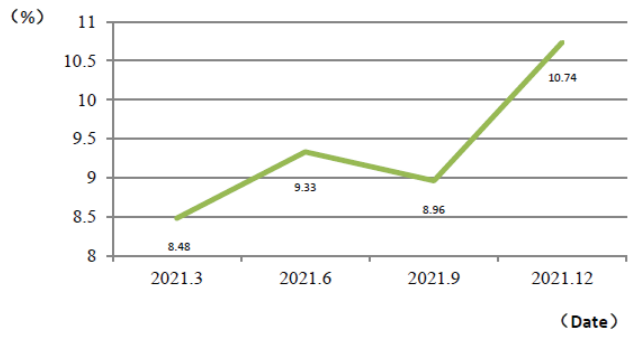

Figure 3: Glycated hemoglobin profile of patients in the past year.

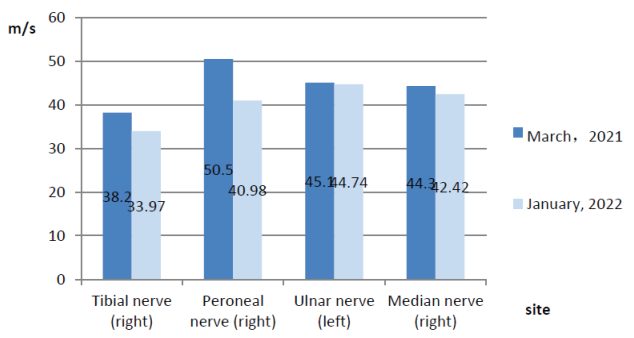

Figure 2: Comparison of neuromotor conduction velocity in March 2021 and January 2022.

reactions most common, including peripheral neuropathy. Two meta-analyses reported the incidence of sensory peripheral nerve damage after the use of programmed death protein-1/programmed death protein ligand-1 inhibitors to be 8.6% and 6.31%, respectively [16,17]. Glucocorticoids as first-line agents have shown good efficacy in ICPis-related demyelinating polyradiculoneuropathy [17]. However, glucocorticoids have not been used in our department during treatment, partly because of poor patient compliance and non-cooperation, and partly because the patient currently has poor glycemic control (Figure 3) and severely declining islet function, the use of glucocorticoids may cause a sharp increase in the patient's blood glucose, which is ultimately difficult to control.

Previous analysis showed [18] that T1DM is mainly seen with PD-1 inhibitor therapy, and its incidence is only 2%. The incidence of ICPis-related thyroid dysfunction is 6%-20%, and PD-1 inhibitor therapy triggers thyroid dysfunction most commonly, with an incidence of

5%-6%.The incidence of T1DMis much lower than that of thyroid dysfunction and pituitary inflammation. However, in this case, thyroid function tests have not been found abnormal since receiving PD-1 antibody treatment until now, and it is possible that this patient has her own susceptibility factors, which increase in the incidence of T1DM.

Some reports showed [2,3] that human leukocyte antigen genotype testing was performed on some T1DM patients. The percentage of those carryingT1DM-susceptible Human Leukocyte Antigen (HLA) genotype was higher than that of the general population. Also one study found that 76% of ICPis-associated diabetic patients carried the type 1 diabetes susceptibility gene HLA-DR4 [2]. We speculate that this patient may carry T1DM susceptibility HLA for the development of ICPis-associated diabetes, and therefore, suggest that patients treated with ICPis should be tested for high-risk HLA to predict the risk of T1DM. Testing of thyroid function indicators is also needed to reduce the occurrence of thyroid function abnormalities.

In conclusion, although ICPis-associated diabetes mellitus is rare, it is rapidly progressive and more dangerous, and should be highly valued in clinical practice, with close attention to blood glucose and glycated hemoglobin, as well as other relevant indicators before and after ICPis treatment. At the same time, electromyography and lower limb vascular ultrasound should be improved during the treatment process to delay the progression of nerve injury and improve the quality of life of patients. At this stage, the treatment of ICPis-associated diabetes combined with ICPis-associated peripheral nerve injury deserves further study. Future exploration of the pathogenesis, risk population prediction and comprehensive management strategies based on a multidisciplinary treatment model is needed [19-22].

References

1. De Filette JMK, Pen JJ, Decoster L, Vissers T, Bravenboer B, et al. (2019) Immune checkpoint inhibitors and type 1 diabetes mellitus: a case report and systematic review. Eur J Endocrinol 181: 363-374.
2. Stamatouli AM, Quandt Z, Perdigoto AL, Clark PL, Kluger H, et al. (2018) Collateral damage: insulin-dependent diabetes induced with checkpoint inhibitors. Diabetes 67: 1471-1480.
3. Clotman K, Janssens K, Specenier P, Weeta I, De Block CEM (2018) Programmed cell death-1 inhibitor-induced type 1 diabetes mellitus. J Clin Endocrinol Metab 103: 3144-3154.
4. Zhang R, Cai XL, Liu L, Han XY, Ji LN (2020) Two case reports of type 1 diabetes mellitus after immune checkpoint inhibitor therapy and review of the literature. Chin Med J 133: 2595-2598.
5. Touat M, Talmasov D, Ricard D, Psimaras D (2017) Neurological toxicities associated with immune-checkpoint inhibitors. Curr Opin Neurol 30: 659-668.
6. Pan PC, Haggiagi A (2019) Neurologic immune-related adverse events associated with immune checkpoint inhibition. Curr Oncol Rep 21: 108.
7. Kao JC, Liao B, Markovic SN, Klein CJ, Naddaf E, et al. (2017) Neurological complications associated with anti-programmed death 1 (PD-1) antibodies. JAMA Neurol 74: 1216-1222.
8. Brahmer JR, Tykodi SS, Chow LQM, Hwu WJ, Topalian SL, et al. (2012) Safety and activity of anti-PD-L1 antibody in patients with advanced cancer. N Engl J Med 366: 2455-2465.
9. Barroso-Sousa R, Ott PA, Hodi FS, Kaiser UB, Tolaney SM, et al. (2018) Endocrine dysfunction induced by immune checkpoint inhibitors: practical recommendations for diagnosis and clinical management. Cancer 124: 1111-1121.
10. Passat T, Touchefeu Y, Gervois N, Jarry A, Bossard A, et al. (2018) Physiopathological mechanisms of immune-related adverse events induced by anti-CTLA-4,anti-PD-1 and anti-PD-L1 antibodies in cancer treatment. Bull Cancer 105: 1033-1041.
11. Chen X, Haggiagi A, Tzatha E, DeAngelis LM, Santomasso B (2019) Electrophysiological findings in immune checkpoint inhibitor-related peripheral neuropathy. Clin Neurophysiol 130: 1440-1445.
12. Chinese Diabetes Society (2021) Chinese guidelines for the prevention and treatment of type 2 diabetes mellitus in China. 2020 Edition. Chinese Journal of Practical Internal Medicine 41: 757-784.
13. Yang XY, Zhang L, Chen X, Du GH (2016) Progress of research on the mechanism of peripheral neuropathy in type 2 diabetes mellitus. Chinese Journal of Pharmacology 32: 598-602.
14. Shi J, Zhang WC (2012) Research progress on the pathogenesis of diabetic peripheral neuropathy. Journal of Shanghai Jiaotong University (Medical Edition) 32: 116-119.
15. Cuzzubbo S, Javeri F, Tissier M, Roumi A, Barlog C, et al. (2017) Neurological adverse events associated with immune checkpoint inhibitors: review of the literature. Eur J Cancer 73: 1-8.
16. Nishijima TF, Shachar SS, Nyrop KA, Muss HB (2017) Safety and tolerability of PD-1/PD-L1 inhibitors compared with chemotherapy in patients with advanced cancer: a meta-analysis. Oncologist 22: 470-479.
17. Luo W, Wang Z, Tian P, Li W (2018) Safety and tolerability of PD-1/PDL1 inhibitors in the treatment of non-small cell lung cancer: a meta-analysis of randomized controlled trials. J Cancer Res Clin Oncol 144: 1851-1859.
18. Barroso-Sousa R, Barry WT, Garrido-Castro AC, Hodi FS, Min L, et al. (2018) Incidence of endocrine dysfunction following the use of different immune checkpoint inhibitor regimens: a systematic review and meta-analysis. JAMA Oncol 4: 173-182.
19. Zecchini JM, Kim S, Yum K, Friedlander P (2018) Development of Bell's Palsy After Treatment With Ipilimumab and Nivolumab for Metastatic Melanoma: A Case Report. J immunother 41: 39-41.
20. Altman AL, Golub JS, Pensak ML, Samy RN (2015) Bilateral facial palsy following iplimumab infusion for melanoma. Otolaryngol Head Neck Surg 153: 894-895.
21. Numata S, Iwata Y, Okamura R, Arima M, Kobayashi T, et al. (2018) Bilateral anterior uveitis and unilateral facial palsy due to ipilimumab for metastatic melanoma in an individual with human leukocyte antigen DR4: A case report. J Dermatol 45: 113-114.
22. Psimaras D, Velasco R, Birzu C, Tamburin S, Lustberg M, et al. (2019) Immune checkpoint inhibitors-induced neuromuscular toxicity: From pathogenesis to treatment. J Peripher Nerv Syst 24: S74-S85.