

## Interferon-a Resulting in Multi-Organ Dysfunction: A Case Report

De-Feng Li<sup>1,2,3\*</sup>, Nan-Nan Wang<sup>3</sup>, Xiao-Xian Jiang<sup>4</sup> and Jun Yao<sup>1</sup>

<sup>1</sup>Department of Gastroenterology, the 2nd Clinical medicine College (Shenzhen People's Hospital) of Jinan University, Shenzhen 518020, China

<sup>2</sup>Integrated Chinese and Western Medicine Postdoctoral research station, Jinan University, Guangzhou 510632, China

<sup>3</sup>Department of Gastroenterology, the First Affiliated Hospital of University of South China, University of South China, Hengyang, 421001, China

<sup>4</sup>Department of Diagnosticimagingology, the First Affiliated Hospital of University of South China, University of South China, Hengyang 421001, China

\*Corresponding author: De-Feng Li, Department of Gastroenterology, the 2nd Clinical medicine College (Shenzhen People's Hospital) of Jinan University, Shenzhen 518020, China, E-mail: [ldf830712@163.com](mailto:ldf830712@163.com)

Received: 10 Sep, 2018 | Accepted: 03 Oct, 2018 | Published: 09 Oct, 2018

**Citation:** Li DF, Wang NN, Jiang XX, Yao J (2018) Interferon-A Resulting in Multi-Organ Dysfunction: A Case Report. J Clin Case Stu 3(4): dx.doi.org/10.16966/2471-4925.176

**Copyright:** © 2018 Li DF, et al. This is an open-access article distributed under the terms of the Creative Commons Attribution License, which permits unrestricted use, distribution, and reproduction in any medium, provided the original author and source are credited.

### Abstract

Drug side effects are sometimes inevitable in clinical practice. They can not only result in mild side effects, such as allergy but also severe side effects, such as multi-organ dysfunction and occasional mortality, contributing to significant economic burden in the world. Therefore, it is urgent to acknowledge the drug side effects. Interferon-a (INF-a) is commonly used in the treatment of various virus infection disorder, such as hepatitis C (HCV) and human papillomavirus (HPV). The most common side effects of INF-a is mild, such as flu-like symptoms, but one must be aware of rare but serious complications of multi-organ dysfunction as in this case.

**Keywords:** Interferon-a; Drug side effects; Multi-organ dysfunction

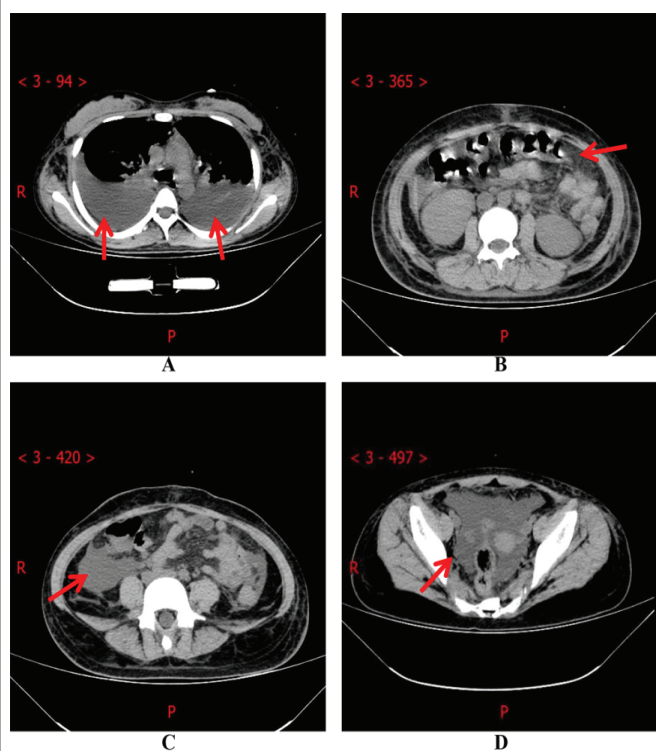
### Case Presentation

Interferon-a (INF-a) is a cytokine associated with early viral infection, has both anti-viral and anti-proliferative properties and commonly use in the treatment of various virus infection disorder, such as hepatitis C (HCV) and human papillomavirus (HPV) [1]. The most common acute side effects are flu-like symptoms, while chronic side effects include hematologic, neuropsychiatric and endocrinological (mainly thyroid) [2]. In this case, we reported acute multi-organ dysfunction during INF-a therapy. A 16-year-old HPV-positive woman presented with a 4-month history of condylomata acuminata on the vulva and received surgical therapy combined with subcutaneous INF-a (300 iu, once a day). Nine days later, she developed gastrointestinal hemorrhage, abdominal pain, high fever and chest tightness shortness of breath. Subsequently, she was admitted to hospital in intensive care unit. On physical examination, she had high-grade fever (39.5C), respiratory rate 22 per minute, heart rate 110 per minute, blood pressure 90/60 mmHg, severe pallor, double pulmonary moist rales, lower abdominal tenderness and rebound tenderness. Initial laboratory value revealed a red blood cell count of  $1.51 \times 10^{12}/L$  ( $3.5-5.0 \times 10^{12}/L$ ), white blood cell count of  $6.83 \times 10^9/L$  ( $4.0-10.0 \times 10^9/L$ ), a hemoglobin (Hb) concentration of 50 g/L (110-150 g/L), a platelet count of  $23 \times 10^9/L$  ( $100-300 \times 10^9/L$ ), activated partial thromboplastin (APTT) of 47.9s (22-43s) a prothrombin time (PT) of 16.4 (9.0-14.5s), international normalized ratio (INR) of 1.42 (0.8-1.3), serum album (ALB) of 22.7 g/L (33-35 g/L), total bilirubin (TLB)

of 16.6  $\mu\text{mol}/L$  ( $3.4-21.0 \mu\text{mol}/L$ ), AST of 742.4 U/L (0-39 U/L), ALT of 3908 U/L (0-40 U/L), fecal occult blood test (+++), arterial blood gas analysis (oxygen 2 L/min, 29%) displaying PH value 7.461 (7.35-7.45),  $\text{SO}_2$  value 99.6% (95%-98%),  $\text{PO}_2$  value 111 mmHg (80-100 mmHg),  $\text{PCO}_2$  value 23 mmHg (35~45 mmHg),  $\text{HCO}_3$  value 18.4 mmol/L (24.1-27.3 mmol/L), blood urine nitrogen (BUN) value 13.3 mmol/L (2.5-7.8 mmol/L), computed tomography (CT) of the chest and abdomen showing pulmonary infection, massive pleural effusion and atelectasis (Figure 1A), blurring and swelling of peritoneum (Figure 1B), few ascites (Figure 1C) and few pelvic effusion (Figure 1D). She was diagnosed with acute multi-organ dysfunction caused by complications of INF-a therapy. Therefore, INF-a was discontinued immediately. The patient received blood products transfusion, liver protection and antibiotics were treated. For 10 days, she recovered uneventfully. However, she refused digestive endoscope and bone marrow biopsy. One month later, laboratory values were normal. In conclusion, it is necessary to monitor blood counts, liver function and kidney function due to side effects of the recent use of INF-a.

### Source of Support

This work was supported by Natural Science Foundation of Hunan Province (No.2017JJ3270), Three Engineering Training Funds in Shen Zhen (No.SYLY201718, No.SYLY201801) and Technical Research and Development Project of Shen Zhen (NO. JCYJ20150403101028164).



**Figure 1:** A: massive pleural effusion (arrow). B: Blurring and swelling of peritoneum (arrow). C: Few ascites (arrow). D: Few pelvic effusion (arrow)

## References

1. Murakami Y, Ishibashi T, Tomita E, Imamura Y, Tashiro T, et al. (2016) Depressive symptoms as a side effect of Interferon- $\alpha$  therapy induced by induction of indoleamine 2,3-dioxygenase 1. *Sci Rep* 6: 29920.
2. Fried MW (2002) Side effects of therapy of hepatitis C and their management. *Hepatology* 36: S237-S244.