

Caecal Schistosomiasis with Perforation: A Case Report at the Korle-Bu Teaching Hospital Accra Ghana

Der EM^{1,2*}, Osman L¹ and Armah R³

¹Department of Pathology, School of Biomedical Sciences, Korle-Bu Teaching Hospital, Accra, Ghana

²Department of Pathology, School of Medicine and Health Sciences, UDS, Tamale, Ghana

³Department of Surgery, School of Biomedical Sciences, Korle-Bu Teaching Hospital, Accra, Ghana

*Corresponding author: Der Muonir Edmund, Department of Pathology, School of Biomedical Sciences, Korle-Bu Teaching Hospital, Accra, Ghana, Tel: 2322444444; E-mail: maadelle@yahoo.com

Received date: 31 Mar 2016; Accepted date: 02 Jun 2016; Published date: 06 Jun 2016.

Citation: Der EM, Osman L, Armah R (2016) Caecal Schistosomiasis with Perforation: A Case Report at the Korle-Bu Teaching Hospital Accra Ghana. J Clin Case Stu 1(4): doi <http://dx.doi.org/10.16966/2471-4925.122>

Copyright: © 2016 Der EM, et al. This is an open-access article distributed under the terms of the Creative Commons Attribution License, which permits unrestricted use, distribution, and reproduction in any medium, provided the original author and source are credited.

Abstract

Background: Caecal perforation commonly occurs in elderly patients with caecal neoplasms or distal obstructions.

Case presentation: We report a case of caecal schistosomiasis with spontaneous perforation in a 40 year old taxi driver in Accra Ghana, who presented with symptoms of acute abdomen. He had emergency laparotomy and right hemicolectomy. Findings at surgery were caecal tumour with perforation at the base and faecal peritonitis. Pathological examination revealed chronic granulomatous response to schistosoma ova with bowel wall necrosis and perforation.

Conclusions: Right iliac fossa pain is a common symptom of acute appendicitis, especially in young patients. However, in rare cases it can reflect other pathology which is easy to miss-diagnose as in this case.

Keywords: Caecum; Schistosomiasis; Acute abdomen; Granulomatous reaction

Introduction

Caecal perforation in a healthy individual is uncommon and if it does, it is commonly associated with distal luminal obstruction, malignancy, unrelieved volvulus of the caecum, trauma to the right side of the abdomen, or iatrogenic [1]. Spontaneous perforation of the caecum in the absence of any of the above factors is exceedingly rare. In the 1990s, cases of spontaneous caecal perforations were reported. Low and Fairley [2] in 1934 described a case of perforation occurring in a patient suffering from tropical sprue. Robertson et al. [3] in 1958 described a case following natural childbirth. Other inflammatory conditions mimicking spontaneous caecal perforations have been reported [4,5]. Again, in 1961 Hirsch also described another case following Caesarean section [6].

Caecal perforation associated with abdominal tuberculosis [7,8] in developing countries has been reported in the literature. Similarly, intestinal schistosomiasis has been reported in Singapore, Ghana [9,10] and other countries in the tropics [11,12]. Spontaneous large bowel perforation associated with intestinal schistosomiasis has been reported in Africa [13]. However, spontaneous caecal perforation resulting from intestinal schistosomiasis in Ghana has not been published from our literature searched. This case report presents rare cause of spontaneous caecal perforation associated with intestinal schistosomiasis in a 40 year old taxi driver, a native of the Eastern Region of Ghana.

Case Report

Mr SF, a 40 year old male driver from Awoshie in the greater Accra Region of Ghana, presented to the Korle-Bu Teaching Hospital (KBTH) surgical medical emergency with a 3 day history of sudden onset of right iliac fossa pain associated with anorexia, fever and chills. He is a native of the Eastern Region of Ghana, where he lived until age 20-years when he migrated to Accra to learn his current profession. At the time of presentation, he was ill-looking, dehydrated and warm to touch. The pulse rate was 102 bpm. He had marked right iliac fossa tenderness and

rebound tenderness, but no guarding. The bowel sounds were present but infrequent.

Laboratory investigations

The haemoglobin level was 14.1 g/dl, WBC was $17.05 \times 10^9/L$ (high) and platelet count was $190 \times 10^9/L$. The Renal function test (BUE&Cr) was Sodium (Na) 135 mmol/L, Potassium (K) 4.1 mmol/L, Urea (SI), 3.1 mmol/L (Low), Creatinine (SI), 3102 $\mu\text{mol/L}$.

Pre-operative diagnosis: Peritonitis 2^o perforated appendix

Mr SF had exploratory laparotomy and right hemicolectomy. The findings at surgery were: gangrenous appendix, caecal tumour with perforation at the base and faecal peritonitis. There were 11 enlarged pericolic lymph nodes.

Post-operative diagnosis: 1. Perforated Caecal tumour 2. Gangrenous Appendicitis

Post-operative management

He had intravenous antibiotics (flagyl and ciprofloxacin), intramuscular pethidine and suppository paracetamol. He had nasogastric tube and urethral catheter passed. He had input-output fluid chart.

Histopathology report

We received a right hemicolectomy specimen consisting of the terminal ileum (11.0 cm long), caecum (8.0 cm long) and the ascending colon (14.0 cm long). There was a perforation (3 × 2 cm) that was posteriorly located and at the base. Opening the bowel revealed a thickened and fibrotic caecal wall associated with necrosis and perforation (Figure 1). The appendix was grossly normal except moderate thickening and fibrosis at the base closed to the perforation. The rest of the specimen was normal grossly. No polyp nor and tumour seen. There were 11 lymph nodes retrieved from the pericolic fat.

Microscopy examination of sections of representative portions from the caecal wall showed large areas of fibrosis, necrosis, haemorrhage and oedema. There were viable and calcified *Schistosoma haematobium* ova within the necrotic area and the submucosa region of the viable bowel wall. No malignancy seen. The 11 lymph nodes retrieved show reactive changes (Figure 2).

Final diagnosis

Caecal schistosomiasis with perforation.

Discharging summary

Mr SF was put on a stat dose of praziquantil (1.2 G) based on the histopathology report and discharged on the post-operative day 10. He was found on his first review to be doing well.

Discussion

Mr. SF presented to the KBTH surgical medical emergency with sudden onset of colicky right iliac fossa pain. He had right hemicolectomy and the final histological diagnosis was caecal schistosomiasis with perforation. The clinical picture of Mr SF mimics most acute abdominal conditions such as acute appendicitis [3,4] that requires immediate surgical management as in this case. The age of Mr SF and the clinical presentation of his condition all put together may have accounted for the pre-operative diagnosis of peritonitis 2^o perforated appendicitis by the surgeons. For instance, appendicitis and spontaneous caecal perforation are common conditions within the age (Younger) group of Mr SF [5].

Caecal perforation associated with luminal obstruction by tumours or trauma has been reported in the literature, [1,6] but these were absent in this case. Infectious causes of spontaneous large bowel perforation such as tuberculosis and schistosomiasis in healthy individuals both rare complications have been reported in the developed and developing countries across the globe [7-13]. The diagnosis of spontaneous caecal perforation due to schistosomiasis in Mr. SF therefore supports previous studies.

Infections by schistosome species are commoner in Asia and Sub-Saharan Africa [14,15] with fresh water bodies and farming as the major occupation [16]. In Ghana, schistosomiasis have major economic and public health implications on residents living in endemic rural and peri-urban areas, [17,18] where people, especially children are predispose to schistosomiasis and its complications decades ago [19-21]. Mr. SF is a native of the East Region of Ghana, a farming community with fresh water bodies (rivers), where he lived up to age 20 years before moving to Accra and thus may have acquired the infection during his childhood. The chronic inflammatory response to the ova resulted in caecal wall fibrosis, ischaemic necrosis and perforation that presented as acute abdomen in this case. The commonly involved species in farming communities of Ghana [10] and other endemic regions in Africa such as Egypt [22,23] decades ago has been identified as *S. haematobium*, and this supported the species identified in this current case report.

The presence of the ova in the vessels and tissues evokes chronic inflammatory response with mark fibrosis and inflammatory mass formation. This inflammatory mass may grossly mimic a neoplasm as in the current case. For instance, post operatively, two of the findings were caecal mass and 11 enlarged lymph nodes, mimicking a neoplastic lesion. This was however found by histological examination to be an inflammatory mass (caecal schistosomiasis). This case further illustrated the difficulty in differentiating an inflammatory mass from a neoplastic lesion at surgery without histopathological study. The treatment of schistosomiasis is praziquantel. Mr. SF had right hemicolectomy because his condition complicated as a mass with necrosis and perforation.

Recommendations

For people particularly children living in schistosome endemic regions of Ghana, to prevent life threaten complications as in this case report, the following are recommended.

1. Routine urine and stool examination for early detection of schistosome infection.
2. Periodic cystoscopy and colonoscopy for people with haematuria and bloody stool, to detect and differential inflammatory lesions from malignant lesions.
3. When indicated computer tomography may employed to determine organs involvements by schistosome species.

Conclusion

Right iliac fossa pain is a common symptom of acute appendicitis, especially in young patients. However, in rare cases it can reflect other pathologies which are easy to miss-diagnose as in this case.

Authors' Contributions

EMD: Ideal of a case report, Histology reporting, Literature review and Reading/correction of manuscript

OL: Histology reporting, Literature review and Reading/correction of manuscript

AR: Clinical history, Surgery and management and Reading/correction of manuscript

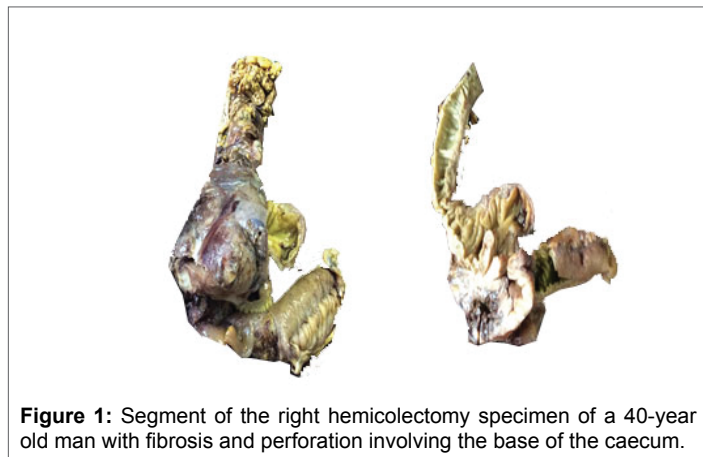


Figure 1: Segment of the right hemicolectomy specimen of a 40-year old man with fibrosis and perforation involving the base of the caecum.

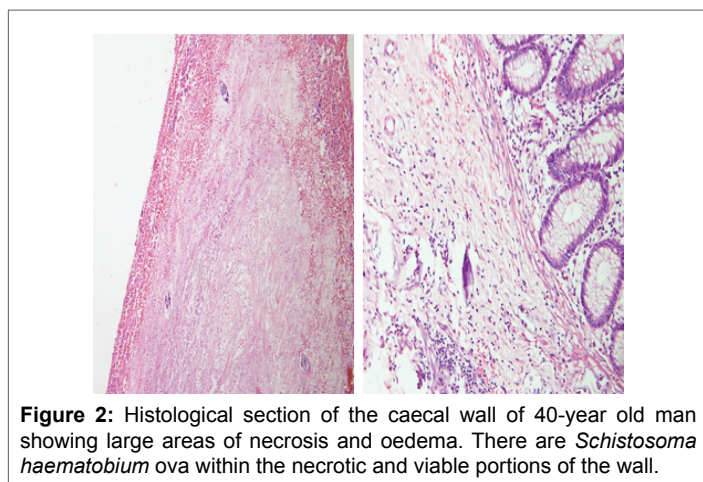


Figure 2: Histological section of the caecal wall of 40-year old man showing large areas of necrosis and oedema. There are *Schistosoma haematobium* ova within the necrotic and viable portions of the wall.

Conflict of Interests

The authors declare that there are no conflicts of interests.

Ethical Considerations

The authors declare that the written consent was obtained from the patient for publication of this case report. The consent is available with the authors.

Funding

None declared

References

- Rack FJ (1952) Obstructive perforation of the cecum; Report of eight cases. *Am J Surg* 84: 527-533.
- Low GC, Fairley NH (1943) Fatal perforation of caecum in case of sprue. *Br Med J* 2: 678-679.
- Robertson JA, Eddy WA, Vosseler AJ (1958) Spontaneous perforation of the cecum without mechanical obstruction. *Am J Surg* 96: 448-452.
- Kumar D, Phillips SF (1987) The contribution of external ligamentous attachments to function of the ileocecal junction. *Dis Colon Rectum* 30: 410-416.
- Malek L, Sultan A, Abbas M, Al-Awadhi N (2009) Perforated caecal diverticulitis mimicking an acute appendicitis: a case report. *Cases J* 2: 7901.
- Hirsh MI (1961) Spontaneous rupture of the caecum. Report of a case. *Cent Afr J Med* 7: 49.
- Clarke DL, Thomson SR, Bisetty T, Madiba TE, Buccimazza I, et al. (2007) A single surgical unit's experience with abdominal tuberculosis in the HIV/AIDS era. *World J Surg* 31: 1088-1097.
- Jain DK, Aggarwal G, Lubana PS, Moses S, Joshi N (2010) Primary tubercular caecal perforation: a rare clinical entity. *BMC Surg* 10: 12.
- Wong MT, Goh L, Chia KH. (2008) Intestinal schistosomiasis manifesting as colonic intussusception arising from a mucocele of the appendix: Report of a case. *Surg Today* 38: 664-667.
- Der EM, Quayson SE, Mensah JE, Tettey Y (2015) Tissue schistosomiasis in Accra Ghana: a retrospective histopathological review at the Korle-Bu Teaching Hospital (2004-2011). *Pathol Discov* 3: 1.
- Malenganisho WL, Magnussen P, Friis H, Siza J, Kaatano G, et al. (2008) Schistosoma mansoni morbidity among adults in two villages along Lake Victoriashores in Mwanza district, Tanzania. *Trans R Soc Trop Med Hyg* 102: 532-541.
- Mazigo HD, Chandika AB, Zinga M, Heukelbach J, Rambau P (2011) Intestinal schistosomiasis associated with intussusception: a case report. *Tanzan J Health Res* 13: 139-141.
- Atik FA, Lopes Filho GJ, Linhares Mde M, Seda Neto J, Mansur NS (1998) Large intestine obstruction complicated with perforation: A rare manifestation of Schistosoma mansoni infection. *Sao Paulo Med J* 116: 1781-1783.
- Lengeler C, Utzinger J, Tanner M (2002) Questionnaires for rapid screening of schistosomiasis in sub-Saharan Africa. *Bull World Health Organ* 80: 235-242.
- King CH, Dickman K, Tisch DJ (2005) Reassessment of the cost of chronic helminthic infection: a meta-analysis of disability-related outcomes in endemic schistosomiasis. *Lancet* 365: 1561-1569.
- Cheesebrough M (2005) District laboratory practice in tropical countries. 2nd edition, Cambridge University Press.
- Taylor M (2008) Global trends in schistosomiasis control. *Bull World Health Organ* 86: 738.
- Nsawah-Nuamah NN, Mensah G, Aryeetey ME, Wagatsuma Y, Bentil G (2001) Urinary schistosomiasis in southern Ghana: a logistic regression approach to data from a community-based integrated control program. *Am J Trop Med Hyg* 65: 484-490.
- Wagatsuma Y, Aryeetey ME, Nkrumah FK, Sack DA, Kojima S (2003) Highly symptom-aware children were heavily infected with urinary schistosomiasis in southern Ghana. *Cent Afr J Med* 49: 16-19.
- Useh MF, Ejezie GC (1999) Modification of behaviour and attitude in the control of schistosomiasis. 1. Observations on water-contact patterns and perception of infection. *Ann Trop Med Parasitol* 93: 711-720.
- Zakhary K (1997) Factors Affecting the Prevalence of Schistosomiasis in the Volta Region of Ghana. *McGill J Med* 3: 93-101.
- Feldmeier H, Poggensee G, Krantz I, Helling-Giese G (1995) Female genital schistosomiasis. New challenges from a gender perspective. *Trop Geogr Med* 47: S2-S15.
- Feldmeier H, Daccal RC, Martins MJ, Soares V, Martin R (1998) Genital manifestations of schistosomiasis mansoni in women: important but neglected. *Mem Inst Oswaldo Cruz* 93: 1127-1133.