Sci Forschen
Open HUB for Scientific Research

Journal of Blood Disorders and Medicine
ISSN 2471-5026 | Open Access

RESEARCH ARTICLE

Volume 5 - Issue 1

Aseptic Osteonecrosis of the Femoral Head in Children Living with Sickle Cell Disease at the National Reference Center for Sickle Cell Disease of Brazzaville, Congo

Galiba Atipo-Tsiba FO[1,2]*, Bilongo-Bouyou ASW[2,3], Gatsongui BM[1], Ngolet LO[1,2], Osseke N[1], Malanda F[1,2], Elira Dockekias A[1,2]

[1]National Reference Center for Sickle Cell Disease, Brazzaville, Congo
[2]Faculty of Health Sciences, Marien Ngouabi University, Brazzaville, Congo
[3]Traumatology-Orthopedics Department, Brazzaville University Hospital, Congo

***Corresponding authors:** Galiba Atipo Tsiba Firmine Olivia, MCA of Clinical Hematology-Marien Ngouabi University of Brazzaville (Congo), Email: atipogaliba@gmail.com

Received: 20 Feb, 2023 | **Accepted:** 24 Mar, 2023 | **Published:** 31 Mar, 2023

Citation: Galiba Atipo-Tsiba FO, Bilongo-Bouyou ASW, Gatsongui BM, Ngolet LO, Osseke N, et al. (2023) Aseptic Osteonecrosis of the Femoral Head in Children Living with Sickle Cell Disease at the National Reference Center for Sickle Cell Disease of Brazzaville, Congo. J Blood Disord Med 5(1): dx.doi.org/10.16966/2471-5026.131

Abstract

Introduction: Aseptic Osteonecrosis of the Femoral Head (AOFH) is a degenerative complication of sickle cell disease. In the absence of care, it is a source of disability through painful lameness and functional impotence that it causes over time. Its data in african children are scarce. This work aimed at determining its prevalence and describing its characteristics.

Methodology: It was about a descriptive study conducted over a4 years- period at the CNRDr on children suffering from homozygous sickle cell disease and presenting with ONFH. The studied variables were epidemiological, clinical and paraclinical, collected from medical records. The Postel Merle-d'Aubigné functional score was used to assess the functional status of the hips and the Arlet and Ficat classification for radiological staging.

Results: The study involved 31 children (18 boys and 13 girls). The prevalence of AOFH was 2.15%. The average age was 11.51 ± 2.17 years old. Almost half were under 11 (45.16%). At diagnosis, the damage was bilateral in 10/31 cases, bringing the number of pathological hips to 41/62. Hip pain was constant and associated with lameness in 83.87% of cases. Hip function was good, fair, and poor respectively in 41.94%, 54.84% and 3.22% of cases. One child presented with two stiff hips. Radiologically, stages I and II on one hand and III and IV on the other hand of Arlet and Ficat were respectively found in 45.16% and 54.84% of cases.

Conclusion: We report one of the most important series of black Africa. AOFH affects young children. The diagnosis is frequently late, made at the stage of functional impotence with joint destruction. The search for predictive factors is important to improve the prognosis of these young patients.

Keywords: AOFH, Children, Femoral Head, Hip, Osteonecrosis, Sickle Cell Disease

Introduction

Sickle cell disease is a genetic disease inducing the polymerization of hemoglobin molecules in red blood cells, causing their embrittlement, hyperhemolysis, and loss of plasticity [1] which is observed in almost all vertebrates, including aquatic animals and birds [2]. The most common hereditary disease in the world, with approximately 310,000 births affected each year [3], it constitutes a public health problem, particularly in sub-saharan Africa where 85% of children affected by the disease are born [4]. In Congo, the homozygous and heterozygous forms represent respectively 1.25% and 25% of the population [5]. The symptomatic forms are characterized by three main categories of clinical manifestations which can vary greatly depending on the case: chronic haemolytic anemia with episodes of acute worsening, predisposition to bacterial infections, and vaso-occlusive manifestations [1].

At the osteoarticular level, the complications are multiple and can manifest themselves either acutely (vaso-occlusive crisis, bone infarction, infections) or chronically (chronic osteomyelitis, aseptic epiphyseal osteonecrosis). Aseptic epiphyseal osteonecrosis is the death of bone tissue occurring outside of infection and relating to an abnormality in blood circulation.

The head of the femur is the most common site (75% of cases) [6-8]. Its frequency increases over time [9]. In Congo, it is the most common chronic complication in adults [10]. When it occurs early, it constitutes an obstacle not only to the growth of the skeleton, but also to the quality of the child's life, already affected by lots of vaso-occlusive crises, by painful lameness and functional impotence that it entails over time [11,12]. Little data exist on AOFH in African children suffering from sickle cell disease. It appears that the diagnosis is most often made at the stage of joint destruction [13,14]. This work aimed at

determining its prevalence and describing its epidemiological, clinical, and radiological characteristics in children suffering from sickle cell disease in Brazzaville, Congo.

Methodology

This was a descriptive cross-sectional study. It was conducted over a 4 years-period from October 1st, 2017 to September 31st, 2021. It took place at the National Reference Center for Sickle Cell Disease "Antoinette Sassou N'guesso" in Brazzaville, which since 2017 has been the largest center in the country dedicated to the care of people suffering from sickle cell disease, research, and health workers' training on the disease. Patients of all ages come from all districts of the country. Apart from any emergency and depending on their age, children are seen there four to six times a year, i.e. at least once a quarter for systematic check-up. An X-ray of the pelvis is prescribed as part of a systematic check-up from the age of 10 and/or if there are signs suggesting AOFH. The target population was constituted of children, i.e. patients under 18, who had radiologically documented AOFH. Sampling was exhaustive consecutively. Data were collected retrospectively from medical records. They were epidemiological (age at diagnosis and gender), clinical (manifestations and functional repercussions of AOFH) and paraclinical (radiological aspects of AOFH). The measurement of the length of the pelvic limbs used as landmarks the umbilicus and the medial malleolus. The Postel Merle d'Aubigner functional score [15] was used to assess the impact of AOFH on hip function. AOFH was classified according to the radiological staging of Arlet and Ficat [16].

The results of the qualitative variables are presented in absolute values and in percentage; those of the quantitative variables in the form of mean (± standard deviation), minimum and maximum.

Results

2982 patients suffering from homozygous sickle cell disease were followed at the National Reference Center for Sickle Cell Disease "Antoinette Sassou N'guesso", including 1623 children. AOFH was documented in 35 of them, which corresponds to hospital prevalence of 2.15%. Thirty-one files were used to describe their characteristics. The average age of the children was 11.51 ± 2.17 years with extremes of 8 and 17 years. They were 18 boys and 13 girls. The sex ratio was 1.38. Hip pain was the discovery circumstance of AOFH in all patients. It was mechanical and associated with lameness in some children. The lameness was analgesic type in 9 children (29.03%) and Trendelenburg type in 17 children (54.84%).

The clinical characteristics of children suffering from sickle cell disease presenting with ONFH are presented in table 1.

Due to the bilaterality of lesions in 10 children (32.26%), there were a total of 41 pathological hips for 31 children. Considering the highest stage in children with bilateral lesions, the radiological staging of AOFH is reported in table 2.

Figure 1 illustrates a right AOFH at stage III of Arlet and Ficat with bone sequestration in a 14-year-old boy living with sickle cell disease.

Table 1: Epidemiological and clinical characteristics of children suffering from sickle cell disease presenting with AOFH on National Reference Center for Sickle Cell Disease of Brazzaville, Congo.

	N%	
Overall	31	100
Gender		
Female	13	41,9
Male	18	58,1
Age group (years)		
≤ 10	14	45.16
11-15	15	48.39
>15	2	6.45
Discovery circumstance		
Isolated hip pain	31	100
Hip pain with lameness	26	83.37
Systematic radiography	-	-
AOFH topography		
Bilateral	10	32.26
Left hip	12	38.71
Right hip	9	29.03
Pelvic bone appearance		
Normal	20	64.52
Asymetric	11	35.48
Length of lower limbs		
Equal	10	32.26
Unequal	21	67.74
Postel Merle d'Aubigner functional score		
Good	13	41.94
Fair	17	54.84
Poor	1	3.22

Table 2: Distribution of children suffering from sickle cell disease presenting AOFH according to Arlet and Ficat radiological stage, at National Reference Center for Sickle Cell Disease of Brazzaville, Congo.

Arlet and Ficat radiological stage	N	%
I	8	25,81
II	6	19,35
III	9	29,03
IV	8	25,81
Total	31	100

Discussion

Our pediatric series is one of the highest among those reported in Africa: Mouba in Gabon reported 22 cases over 10 years [13]. Akakpo-Numado in Togo reported 14 (including 8 HbSS and 6 HbSC) over a period of 20 years, but these were data from a pediatric surgery department and not from a treatment center for sickle cell disease [14]. The diagnosis was based solely on the realization of a standard X-ray of the pelvis. The prevalence of AOFH in our study and in general in Africa is probably much under estimated. Indeed, the systematic non-practice of MRI or bone scintigraphy constitutes a limit to the early diagnosis of osteonecrosis in patients (symptomatic or not) presenting a normal standard X-ray. This fact was objectified by Kouamé-Koutouan in Côte-d'Ivoire where the prevalence of AOFH in adults with sickle cell disease presenting coxalgia with or without lameness doubled thanks to the use of bone scintigraphy, half patients with a normal plain radiograph [17]. In addition, the annual systematic screening recommended by expert groups [18] cannot be applied due to the absence of social security systems limiting access to care. Thus much higher frequencies of AOFH are reported in so-called rich

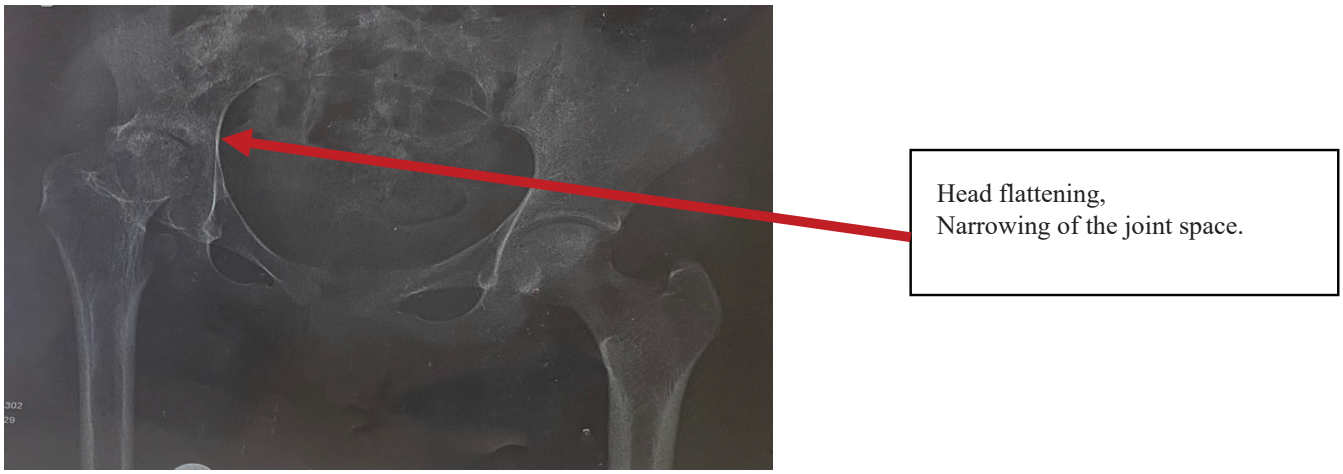

Figure 1: X-ray of the pelvis illustrating a right AOFH at stage IV of Arlet and Ficat in a 14-year-old girl suffering from sickle cell disease.

countries where routine radiographic screening for AOFH is carried out in the majority of patients, symptomatic or not: from 9% in the USA(Philadelphia) in the study by Worrall between 0 and 21 years old [19], to 14.13% in Brazil between 0 and 20 years old [20,21]. Still in the USA (New York), Mahadeo reports a prevalence of all genotypes of 12.4% which increases to 14.2% for the HbSS and HbSβ0 thalassemia forms in patients aged 10 to 21 years [22]. Several risk factors are implicated in the occurrence of osteonecrosis in sickle cell disease. Among clinical and laboratorial factors, the most promising risk factors were the severity of sickle cell disease and acute chest syndrome. As a result, from studies of a moderate level of quality, blood pressure, body weight, previous trauma, haemoglobin to haematocrit ratio, and number of hospitalizations can be highlighted. Others, such as genetic markers and male gender, have also been positively associated [23,24]. It seems important to research them in the African context.

In our study, the mean age at the time of diagnosis of AOFH of 11.51 ± 2.17 years is slightly lower than that found in the literature, which often varies from 12 to 14 years [12, 24-27]. However, these studies report a slightly younger age of onset: 7 years [13,28], 6 years [26] and even 5 years for osteonecrosis of the shoulder [27]. The particularity of our serie is that nearly half of the children were under 11 years old (45.16%), whereas Mouba [13] and Man and Koren [27] reported a prevalence of AOFH clearly greater after the age of 11. The average age is 14 in Brazil and the USA [19,20]. All these results testify to the early onset of this bone complication diagnosed in sometimes young children.

The pain of AOFH is either acute during the infarction, or chronic during the progressive constitution of osteoarthritic lesions, then accompanied by a reduction in joint mobility [3]. In our study, the diagnosis was made in all patients at a symptomatic stage in which hip pain was the constant sign. None of the diagnosis was systematic. In addition, our data showed a high proportion of children in whom bone damage was bilateral (one-third of cases), classified at the two most advanced stages of Arlet and Ficat (stage II or III in almost two-thirds of cases) and presenting functional impotence (two-thirds of cases). This profile is common in Africa and most likely linked to diagnostic delay, itself related to various social and/or economic reasons, as pointed out by other authors [13,27]. Bilaterality of osteonecrosis lesions over time is usual [29]. Its frequency can reach 91% of adults for hip joints [30]. Our series is characterized by a high rate of bilaterality compared to that of other pediatric series: 20% in Gabon [13] and 18% in Benin [27]. In Mahadeo's study in the USA [22], the diagnosis was made at an earlier stage: 68.75% of patients were asymptomatic, 64% of AOFH corresponded to Steinberg's early stages 1 or 2 [31] and the bilateral damage only concerned 12% of patients whose average age was 18 years, compared to 32% of bilaterality in ours whose average age, it should be remembered, was 11 years.

Conclusion

Our findings reflect the early onset of AOFH in african children suffering from sickle cell disease in Africa and its late diagnosis, most often at the stage of joint destruction. To overcome this, special emphasis should therefore be placed on its prevention, at least on the means of delaying its onset. It is important to identify its predictive factors through further investigation in a larger population and to put in place a strategy for early diagnosis such as screening radiographs of the hips from the age of 7.

References

1. Odièvre MH, Quinet B (2022) Drépanocytose chez l'enfant. J de Pédiatrie et de Puéric 35: 73-92.
2. Moradi S, Omar A, Zhou Z, Agostino A, Gandomkar Z, et al. (2022) The ameliorative role of ascorbic acid against blood disorder, immunosuppression, and oxidative damage of oxytetracycline in rainbow trout (Oncorhynchus mykiss). Fish Physiol Biochem 48: 201-213.
3. Piel FB, Patil AP, Howes RE, Nyangiri OA, Gething PW, et al. (2013) Globalepidemiology of Sickle haemoglobin in neonates: A contemporary geostatistical modelbased map and population estimates. Lancet 381: 142-151.
4. Piel FB, Patil AP, Howes RE, Nyangiri OA, Gething PW, et al. (2010) Global distribution of the sickle cell gene and geographical confirmation of the malaria hypothesis. Nat Commun 1: 104.
5. Dokekias AE, Ocko Gokaba LT, Louokdom JS, Ocini LN, AtipoTsiba FOG, et al. (2022) Neonatal Screening for Sickle Cell Disease in Congo. Anemia 1-6.
6. Milner PF, Kraus AP, Sebes JI, Sleeper LA, Dukes KA, et al. (1991) Sickle cell disease as a cause of osteonecrosis of the femoral head. N Engl J Med 325: 1476-1481.

7. Naseer ZA, Bachabi M, Jones LC, Sterling RS, Khanuja HS (2016) Osteonecrosis in Sickle Cell Disease. South Med J 109: 525-530.

8. Zomalhèto Z, Baglo T, Gounongbé M, Dossou-yovo H (2018) Lésions ostéo-articulaires de la drépanocytose au Centre National Hospitalo-Universitaire de Cotonou (Bénin). Rev Mar Rhum 44: 54-57.

9. Santos ACAD, Gusmão ADC, Magalhães NNS, EspositoTS, Fabri JC, et al. (2022) Necrose Avascular Óssea Em Doença Falciforme: Aspectos De Um Estudo Longitudinal. Hematol, Transfus Cell Ther 44: S16-S17.

10. Ngolet LO, Okouango Nguelongo Ova JD, Ntsiba H, Elira DA (2017) Complications chroniques du sujet drépanocytaire adulte à Brazzaville. Heal Sci Dis 18: 56-59.

11. Malheiros CD, Lisle L, Castelar M, Sá KN, Matos MA (2015) Hip dysfunction and quality of life in patients with sickle cell disease. Clin Pediatr (Phila) 54: 1354-1358.

12. Matos MA, Silva LLS, Alves GB, Alcântara Júnior WS, Veiga D (2018) Necrosis of the Femoral Head and Health-Related Quality of Life of Children and Adolescents. Acta Ortop Bras 26: 227-230.

13. Mouba JF, Mimbila M, Lentombo LE, Thardin JF, Ondo A (2011) Nécrose aseptique de la tête fémorale chez l'enfant drépanocytaire: expérience de Libreville (Gabon). Santé 21: 89-92.

14. Akakpo-Numado G, Gnassingbe K, Sakiye KA, Boume MA, Amadou A, et al (2008) Les ostéonécroses aseptiques de la tête fémorale chez l'enfant drépanocytaire. Santé 18: 231-233.

15. Merle D'Aubigne R (1990) Cotation chiffrée de la fonction de la hanche. Rev Chir Orthop 76: 371-374.

16. Arlet J, Ficat P (1977) Non-traumatic avascular femur head necrosis. New methods of examination and new concepts. Chir Narzadow Ruchu Ortop Pol 42: 269-276.

17. Kouame-Koutouan A, Aboukoua-Kouassi N, Koffi D, Méité M, Sanogo I, et al. (2009) Nouvelle stratégie dans le diagnostic, la prévention et le suivi de l'ostéonécrose drépanocytaire en Côte d'Ivoire à partir de la scintigraphie osseuse. Med Nucl 33: 604-608.

18. Habibi A, Arlet JB, Stankovic K, Gellen-Dautremer J, Ribeil JA, et al. (2015) Recommandations françaises de prise en charge de la drépanocytose de l'adulte: actualisation 2015 French guidelines for the management of adult sickle cell disease: 2015 update. Rev Med Interne 36: 5S3-5S84.

19. Leandro MP, De Sá CKC, Filho DPS, De Souza LAA, Salles C, et al. (2021) Association and Risk Factors of Osteonecrosis of Femoral Head in Sickle Cell Disease: A Systematic Review. Indian J Orthop 56: 216-225.

20. Leandro MP, Almeida ND, Hocevar LS, Sá CKC, Souza AJ, et al. (2022) Polymorphisms and avascular necrosis in patients with sickle cell disease-A systematic review. Rev Paul Pediatr 40.

21. Worrall D, Smith-Whitley K, Wells L (2016) Hemoglobin to Hematocrit Ratio: The Strongest Predictor of Femoral Head Osteonecrosis in Children with Sickle Cell Disease. J Pediatr Orthop 36: 139-144.

22. Almeida-Matos M, Carrasco J, Lisle L, Castelar M (2016) Avascular necrosis of the femoral head in sickle cell disease in pediatric patients suffering from hip dysfunction. Rev Salud Publica (Bogota). 18: 986-995.

23. Botelho VL, Silva ICF, Daltro PB, Silva ICF, Souza da Fonseca RJ, et al. (2020) Prevalence of Femoral Head Ostenecrosis in Patients with Falciform Anemia: A Bibliographic Review in Pediatrics. Int J Pediatr Res 6: 1-5.

24. Mahadeo KM, Oyeku S, Taragin B, Rajpathak SN, Moody K, et al. (2011) Increased prevalence of osteonecrosis of the femoral head in children and adolescents with sickle-cell disease. Am J Hematol 86: 806-808.

25. Daltro G, Franco BA, Faleiro TB, Rosário DAV, Daltro PB, et al. (2018) Osteonecrosis in sickle cell disease patients from Bahia, Brazil: a cross-sectional study. Int Orthop 42: 1527-34.

26. Adekile AD, Gupta R, Al-Khayat A, Mohammed A, Atyani S, et al. (2019) Risk of avascular necrosis of the femoral head in children with sickle cell disease on hydroxyurea: MRI evaluation. Pediatr Blood Cancer 66.

27. Man S, Koren A (1993) Avascular necrosis of bones in children with sickle cell anemia. Pediatr Hematol Oncol 10: 385-387.

28. Hans-Moevi AD, Kpadonout T, Biaouo O, Label C, Rahimy MCD (2010) Résultats préliminaires de la prise en charge ambulatoire de la nécrose aseptique de la tête fémorale chez les enfants atteints de drépanocytose. Rev CAMES 10:125-29.

29. Arnal C, Girot R, Tenon H (2002) Drépanocytose chez l'adulte. Hématologie.

30. Hernigou P, Galacteros F, Bachir D, Goutallier D (1991) Deformities of the hip in adults who have sickle-cell disease and had avascular necrosis in childhood. A natural history of fifty-two patients. J Bone Joint Surg (Am) 73: 81-92.

31. Steinberg M, Hayken GD, Steinberg DR (1995) A quantitative system for staging avascular necrosis. J Bone Joint Surg (Br) 77: 34-41.