

Pleomorphic Adenoma-Rare Soft Tissue Tumor of the Hand: Case Report and Literature Review

Joseph S Weisberger^{1,*}, Alexandra Naides¹, Roberto Noland Mora¹, Lauren Otaguro¹, John B Park², Pratik Deb³, Seena Aisner³, and Ramazi O Dattashvili¹

¹Department of Plastic and Reconstructive Surgery, Rutgers New Jersey Medical School, Newark, New Jersey, USA

²Department of Plastic and Reconstructive Surgery, Rutgers Robert Wood Johnson Medical School, New Brunswick, New Jersey, USA

³Department of Pathology, Rutgers New Jersey Medical School, Newark, New Jersey, USA

***Corresponding author:** Joseph S Weisberger, Department of Plastic and Reconstructive Surgery, Rutgers New Jersey Medical School, Newark, New Jersey, USA, Tel: 973 972 1129; E-mail: Jsw173@njms.rutgers.edu

Received: 18 Apr, 2023 | **Accepted:** 09 Jun, 2023 | **Published:** 26 Jun, 2023

Citation: Weisberger JS, Naides A, Mora RN, Otaguro L, Park JB, et al. (2023) Pleomorphic Adenoma-Rare Soft Tissue Tumor of the Hand: Case Report and Literature Review. J Surg Open Access 9(3): dx.doi.org/10.16966/2470-0991.272

Copyright: © 2023 Weisberger JS, et al. This is an open-access article distributed under the terms of the Creative Commons Attribution License, which permits unrestricted use, distribution, and reproduction in any medium, provided the original author and source are credited.

Abstract

Pleomorphic adenomas, also known as mixed tumors, are the most common benign tumors of salivary glands. Over the past two decades only 24 cases of arising in the fingers or hands have been reported in the literature. Herein, we present a historical background of soft tissue mixed tumors, and we report the clinical case of a soft tissue neoplasm of the hand in a 55-year-old male. The 10-year-old, slow-growing lesion was excised from the right hypothenar muscle compartment. On pathologic analysis, the lesion was determined to be a benign pleomorphic adenoma.

Keywords: Hand tumor; Pleomorphic adenoma

Case Report

A 55-year-old right-hand dominant manual worker man, presented for an evaluation of a mass on the hypothenar eminence of the right hand. The mass had been present for 10 years and was slow growing during that time more and more affecting the function of the hand. He had no specific trauma to the right hand acutely or in the past. Past medical history is significant for well-controlled diabetes mellitus type II. Surgical history is non-contributory. On exam, the mass measured 4.5 × 4 × 2 cm and was rubbery soft, immobile, and mildly tender. He was neurovascularly intact in all his right-hand digits. He had full range of motion.

Plain X-ray of the hand showed normal bone mineralization and alignment; joint spaces were preserved, and no fractures were present. A soft tissue mass was visualized over the right hypothenar eminence with no associated calcifications. An ultrasound of the mass showed a predominately cystic mass measuring 3.5 × 2.3 × 3.4 cm. Vascular perfusion was noted at the periphery of the mass. Fluid and debris were also present. Differential diagnoses included complex ganglion cyst, post inflammation/infection, cystic neoplasm, and tenosynovitis.

The decision was made to excise the mass to alleviate morbid symptoms associated with it and to improve the patient's hand function. A 4 cm transverse incision was made along the apex of the lesion and the dissection was carried out using a combination of blunt and sharp dissection. The mass was found to be under the palmar aponeurosis and within the muscle of the hypothenar compartment (Figure 1). The muscle was carefully dissected away from the mass

and the mass was removed en bloc. The wound was irrigated, and hemostasis was achieved. Excess of expanded by tumor skin was removed, and the incision closed.

On pathologic evaluation, the mass was found to be a benign pleomorphic adenoma. The lesion consists of variably epithelioid or more tapering myoepithelial cells, positive for keratins CK7 and AE1/AE3, diffusely positive for S100 protein and PLAG1. The lesion was negative for CD34, INI-1, HMB45, p63, SMA, and desmin. There was a focally myxochondroid matrix and there are multifocally scattered ductal structures with no signs of atypia (Figure 2).

There were no postoperative complications. Sutures were removed in 2 weeks after surgery. The patient was seen in the office one month later. The post incisional scar was in satisfactory condition. Patient had no neurovascular deficits and Tinel sign was negative. He had return to work not having any problems. No other interventions are planned for the patient, and he was instructed to follow-up as needed.

Literature Review

Initially described by Billoth in 1859, pleomorphic adenomas have become recognized as the most common benign salivary gland neoplasms, most commonly found in the parotid gland [1-3]. Since then pleomorphic adenomas have also been referred to as mixed tumors of the salivary glands due to their epithelial and mesenchymal composition [1,4,5].

Historically, only identified in salivary glands, histologically similar mixed tumors were described in distant tissues under the proposition

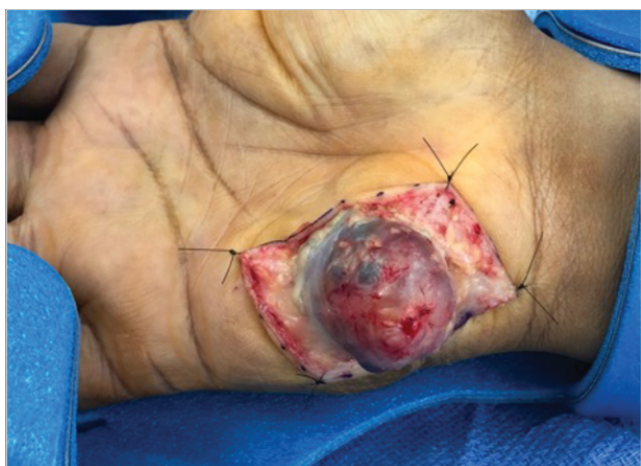

Figure 1: Intraoperative image of the mass within muscle of the hypothenar compartment.

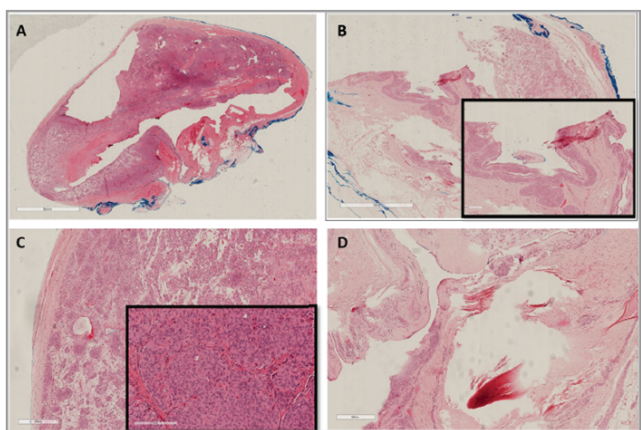


Figure 2: Photomicrographs showing histomorphology of the mass. (A) Scanning histological view of the neoplasm showing a well-circumscribed mass (H&E, 20X). (B) Photomicrograph showing syringomatous component of the mass (H&E, 20X; inset, H&E, 40X). (C) Photomicrograph showing a neoplasm composed of myofibroblasts in a myxoid matrix. Inset showing higher magnification of the myofibroblasts with minimal atypia and mitotic activity (H&E, 40X; inset, H&E, 100X). (D) Neoplasm involving a hair-follicle showing possible adnexal origin (H&E, 40X).

of ectopic embryonal salivary gland tissue origin [6-11]. Though generally benign, pleomorphic adenomas were soon reported to recur after excision, and rarely they possess metastasis potential resulting in mainly histologically benign metastases [12,13]. The most common sites of metastasis have been reported to be bone, head, neck, lung, liver, skin and breast-years or decades after initial presentation, even without recurrence at the primary site [12,14-16].

Most notably, reviews of case reports in the 1950s of so named mixed tumors of skin of salivary gland type led to the recognition of salivary-gland-independent cutaneous tumor histogenesis and their reclassification as chondroid syringomas [17,18]. Eventually, further case reports and reviews presented pleomorphic adenomas and myoepitheliomas-a related myoepithelial tumor without ductal differentiation-arising in other organs including, but not limited to

esophagus, breast, lacrimal glands, and kidneys [19-21]. However, it was not until the late 1990s when more comprehensive reports of mixed tumors and myoepitheliomas occurring in soft tissues appeared in the literature. Similar to salivary mixed tumors, the majority of reported mixed tumors of soft tissues have been classified as benign with a subset of these recurring, leading to malignancy, or metastasizing [22,23,25].

In 1997, Kilpatrick, et al. presented 19 cases of extra salivary soft tissue pleomorphic adenomas and myoepitheliomas occurring principally in the extremities which they described morphologically and by immunohistochemical staining [23]. In 2002 the WHO Classification of Soft Tissue Tumors was updated and concluded that myoepithelial neoplasms, classified under Tumours of Uncertain Differentiation, appeared primarily in soft tissue of the limbs mainly in subcutaneous or deeper tissues. These tumors shared similar morphology to their salivary counterparts, which were primarily benign, occurred mainly in adults, and ~15% were mixed tumors [24].

In 2003, Hornick and Fletcher published a comprehensive study of 101 cases of soft tissue myoepithelial tumors [25]. Therein, they reported that nearly 20% of the cases were pleomorphic adenomas, with most of the remaining tumors being myoepitheliomas without evidence of ductal differentiation. They further reported that unlike their salivary counterparts, these tumors showed no female sex predilection [1,2]. In 2007, Gleason and Fletcher analyzed a series of 29 pediatric cases of soft tissue myoepithelial carcinoma. Among their findings, they concluded that compared to salivary myoepithelial carcinomas that frequently arise in association with benign pleomorphic adenomas or myoepitheliomas in up to 50% of cases, myoepithelial carcinomas of soft tissue arose in association to a benign tumor in less than 7% of their cases [26].

One of the most common genetic markers implicated in salivary gland pleomorphic adenoma was determined to be Pleomorphic Adenoma Gene 1 (PLAG1) a developmentally regulated zinc-finger in 8q12 [27,28]. In 2012, Bahrami A, et al. [29], presented 20 cases of benign soft tissue and skin myoepitheliomas and mixed tumors. Therein, they explored the hypothesis of a genetic linkage to salivary gland counterparts through a common genetic target. They demonstrated genetic rearrangement of PLAG1 in soft tissue tumors in 8 of 11 mixed tumors in their tumor series. In 2013, Antonescu CR, et al. [30], presented a further 35 skin and soft tissue myoepithelial tumors which lacked EWSR1 and FUS gene rearrangements which had previously been associated with soft tissue myoepitheliomas [30,31]. PLAG1 rearrangements were detected in 13 (37%) of the lesions, three (33%) in skin, and 10 (38%) in soft tissue; 12 of these lesions represented 50% of pleomorphic adenomas in their series.

Both the studies by Bahrami and Antonescu concluded that the combination of histomorphological and immunohistochemical staining similarity and presence of PLAG1 rearrangement present evidence of linkage between salivary and soft tissue pleomorphic adenomas. Furthermore, these studies along with results presented by Matsuyama A, et al. [32] further suggested that soft tissue pleomorphic adenomas and myoepitheliomas are genetically distinct as the also found no PLAG1 rearrangement expression in the seven cases of soft tissue myoepithelioma that they presented.

The work to describe report and characterize pleomorphic adenomas and myoepithelial tumors of soft tissue has continued which has led to the refinement of their classification-expanding on their localization, clinical features, histopathology, immunohistochemistry, genetics, and diagnosis-this has been summarized in reviews by Jo VY and Fletcher

CD in 2015, by Jo VY in 2020, and in the latest 2020 5th Edition. WHO Classification of Tumours of Soft Tissue [33-35].

Discussion and Conclusion

As previously presented, though extrasalivary pleomorphic adenomas and myoepitheliomas have been reported by Halpert since at least 1933, it was not until the past 25 years that soft tissue myoepithelial neoplasms started to be properly described and categorized as related but independent entities to salivary gland myoepithelial tumors-with similarities and differentiating properties.

Lesions tend to be painless, slow-growing, and well-circumscribed, but unencapsulated, with a reported mean size of 3.8 cm. Grossly, they can appear white-yellow or tan with a gelatinous or firm and fleshy cut surface; malignant lesions may show hemorrhage and rarely necrosis [35,36]. With a reported peak incidence between the third and fifth decades, soft tissue benign myoepithelial neoplasms show no sex predilection. Interestingly 20% of extra-salivary pleomorphic adenomas occur in the pediatric population, with the majority of these masses having malignant characteristics [22,25,26].

Histological examination of pleomorphic adenomas/mixed tumors, similarly to their salivary gland equivalents, reveals varied cellular and architectural morphologies, both within and between lesions. The diverse cellular and architectural pleomorphism, consisting of epithelial and myoepithelial cells amidst a variety of mesenchymal stroma, which gives rise to its names, is from monoclonal epithelial divergent differentiation. Cells can have a spindled, epithelioid appearance with clear to eosinophilic cytoplasm, they may also appear plasmacytoid/ovoid with hyaline cytoplasmic inclusions. The stroma can be chondroid, myxoid, chondromyxoid, hyalinized, fibrous, and rarely osseous or adipose in nature. Though mainly pleomorphic, some lesions may show a predominant cytological (nests, clusters, sheets, or chords) or growth pattern (reticular or trabecular). Pleomorphic adenomas/mixed tumors and myoepitheliomas have been proposed to be on a morphological spectrum/continuum, with presence of epithelial ductal differentiation-even if highly localized-as the main histological criterion in classifying them as mixed tumors; with current literature estimating mixed tumors to represent ~10% of myoepithelial neoplasms [26,35-38].

On immunohistochemistry, most soft tissue pleomorphic adenomas are positive for keratins (including AE1/AE3), S-100, EMA, GFAP, SOX10, PLAG1, and show retention of SMARCB1 [23,25,26,30,31]. SMARCB1 loss is associated with myoepithelial carcinoma [39,40]. They are also commonly negative for desmin, CD34, and p63. Though positive PLAG1, is indicative of PLAG1 rearrangement in 8q12, it is not specific enough by itself, but is useful in narrowing a diagnosis as it is negative in soft tissue myoepitheliomas-it can facilitate their differentiation in cases of little or highly focal ductal differentiation [33,35-37].

In contrast to salivary myoepithelial tumors, infiltration of soft tissue tumor margins is not associated with malignancy; rather, moderate to severe nuclear atypia (vesicular/coarse chromatin, prominent nucleoli, nuclear pleomorphism) is currently the only known basis for classification as myoepithelial carcinoma which also primarily arises de novo. Benign lesions, however, have a ~20% risk of recurrence and excision with negative margins is recommended [36].

Due to their rarity, their pleomorphic morphology, and the fact that primary soft tissue myoepithelial neoplasms lack a normal cellular counterpart (as opposed to primary salivary gland lesions), their consideration in initial differential diagnoses can be easily overlooked.

Another important consideration in their diagnosis is the possibility of salivary mixed tumor metastases that may occur years after initial presentation and in some cases predate detection at the primary site [41].

Although the soft tissue mixed tumors reported in the literature have a predilection for extremities, there are only a few instances reported in the hands. In the 1950 survey by Halpert and Hackney, they reported 12 tumors of salivary gland type, 10 in fingers and two in the hand. However, they were not identified as specifically of the pleomorphic type and were not individually presented [7]. In 1959, Stout and Gorman reported 10 cases of mixed tumors of salivary gland types in the hand, but specifically of the skin [13]. Hirsch presented 4 more cases of chondroid syringoma in the fingers and hand in 1961. 18 of the 19 cases in the series presented by Kilpatrick SE, et al. [23] in 1997, of extrasalivary mixed tumors of soft tissue, only two were briefly reported to occur fingers, and a third case to occur in the right hand [22]. In the 2003 series of 101 myoepithelial tumors of soft tissue, Hornick and Fletcher summarize 3 cases in the fingers and 5 in the hand, with only one of the latter specifically described and only noted as myoepithelial carcinoma with pleomorphic epithelioid cells in a 71-year-old female [25].

The case presented by Shimosawa et al. in 2009 was the first and only thorough report in the English literature of a rare soft tissue pleomorphic adenoma of the hand [42]. Similarly to our case, the lesion presented by Shimosawa was localized to the right hypothenar region. However, more specifically, that lesion was subcutaneous and overlying the palmar aponeurosis. The lesion in our report was found under the palmar aponeurosis and within the muscle of the hypothenar compartment making it, to our knowledge, the first reported instance of a deep soft tissue pleomorphic adenoma of the hand.

Disclosure

The authors report no conflicts of interest in this work.

References

1. Fletcher CDM (2020) Diagnostic Histopathology of Tumors. 2nd Volume, 5th edition, Philadelphia: Elsevier 303-304.
2. Gnepp DR, Bishop JA (2021) Gnepp's Diagnostic Surgical Pathology of the Head and Neck. 3rd edition, Elsevier 457-462.
3. Billroth T (1859) Beobachtungen über Geschwülste der Speicheldrüsen. Archiv für pathologische Anatomie und Physiologie und für klinische Medizin 17: 357-375.
4. Virchow R (1863) Die krankhaften Geschwülste: dreissig Vorlesungen, gehalten während des Wintersemesters 1862-1863 an der Universität zu Berlin. Berlin: Verlag von August Hirschwald 1: 481.
5. Minssen H (1874) Uebergemischte Geschwülste der Parotis. Hofer.
6. Halpert B (1933) Salivary Gland Tumors in Rare Sites Report of Two Cases. Yale J Biol Med 5: 469-471.
7. Halpert B, Tool CD (1947) Anlage tumors of the salivary glands. Cancer Res 7: 346-350.
8. Halpert B (1949) Mixed tumors of anlage origin. Surgery 26: 1046-1048.
9. Halpert B, Hackney VC (1950) Anlage Tumors of the Salivary Gland Type in Unusual Sites. Surgery 27: 609-615.

10. Halpert B (1950) Anlage tumors of the salivary glands in unusual sites. *Tex Rep Biol Med* 8: 147-153.
11. Halpert B, Brelsford HJ (1954) Mixed tumors in unusual sites. *Surgery* 35: 901-908.
12. Mulligan R (1943) Metastasis of mixed tumors of the salivary glands. *Arch Path* 35: 357-365.
13. Schreibstein JM, Tronic B, Tarlov E, Hybels RL (1995) Benign metastasizing pleomorphic adenoma. *Otolaryngol Head Neck Surg* 112: 612-615.
14. Chen KT (1978) Metastasizing pleomorphic adenoma of the salivary gland. *Cancer* 42: 2407-2411.
15. Olson GW (1937) Pulmonary metastases occurring from aberrant mixed salivary gland tumors. Report of three cases and discussion. *The Laryngoscope* 47: 252-262.
16. Youngs GR, Scheuer PJ (1973) Histologically benign mixed parotid tumour with hepatic metastasis. *J Pathol* 109: 171-172.
17. Stout AP, Gorman JG (1959) Mixed tumors of the skin of the salivary gland type. *Cancer* 12: 537-543.
18. Hirsch P, Helwig EB (1961) Chondroid syringoma. Mixed tumor of skin, salivary gland type. *Arch Dermatol* 84: 835-847.
19. Chen CL, Chen CH, Tai MC, Lu DW, Cheng MF, et al. (2005) Pleomorphic adenoma of the lacrimal gland in a nine-year-old child. *Clin Exp Ophthalmol* 33: 639-641.
20. Moran CA, Suster S, Carter D (1990) Benign mixed tumors (pleomorphic adenomas) of the breast. *Am J Surg Pathol* 14: 913-921.
21. Banducci D, Rees R, Bluett MK, Sawyers JL (1987) Pleomorphic adenoma of the cervical esophagus: a rare tumor. *Ann Thorac Surg* 44: 653-655.
22. Klijanienko J, Servois V, Jammet P, Validire P, Pouillart P, et al. (1998) Pleomorphic adenoma. *Am J Surg Pathol* 22: 772-773.
23. Kilpatrick SE, Hitchcock MG, Kraus MD, Calonje E, Fletcher CD (1997) Mixed tumors and myoepitheliomas of soft tissue: a clinicopathologic study of 19 cases with a unifying concept. *Am J Surg Pathol* 21: 13-22.
24. Fletcher CD (2006) The evolving classification of soft tissue tumours: an update based on the new WHO classification. *Histopathology* 48: 3-12.
25. Hornick JL, Fletcher CD (2003) Myoepithelial tumors of soft tissue: a clinicopathologic and immunohistochemical study of 101 cases with evaluation of prognostic parameters. *Am J Surg Pathol* 27: 1183-1196.
26. Gleason BC, Fletcher CD (2007) Myoepithelial carcinoma of soft tissue in children: an aggressive neoplasm analyzed in a series of 29 cases. *Am J Surg Pathol* 31: 1813-1824.
27. Kas K, Voz ML, Röijer E, Aström AK, Meyen E, et al. (1997) Promoter swapping between the genes for a novel zinc finger protein and beta-catenin in pleiomorphic adenomas with t(3;8) (p21;q12) translocations. *Nat Genet* 15: 170-174.
28. Voz ML, Agten NS, Van de Ven WJ, Kas K (2000) PLAG1, the main translocation target in pleomorphic adenoma of the salivary glands, is a positive regulator of IGF-II. *Cancer Res* 60: 106-113.
29. Bahrami A, Dalton JD, Krane JF, Fletcher CD (2012) A subset of cutaneous and soft tissue mixed tumors are genetically linked to their salivary gland counterpart. *Genes Chromosomes Cancer* 51: 140-148.
30. Antonescu CR, Zhang L, Shao SY, Mosquera JM, Weinreb I, et al. (2013) Frequent PLAG1 gene rearrangements in skin and soft tissue myoepithelioma with ductal differentiation. *Genes Chromosomes Cancer* 52: 675-682.
31. Antonescu CR, Zhang L, Chang NE, Pawel BR, Travis W, et al. (2010) EWSR1-POU5F1 fusion in soft tissue myoepithelial tumors. A molecular analysis of sixty-six cases, including soft tissue, bone, and visceral lesions, showing common involvement of the EWSR1 gene. *Genes Chromosomes Cancer* 49: 1114-1124.
32. Matsuyama A, Hisaoka M, Hashimoto H (2012) PLAG1 expression in mesenchymal tumors: an immunohistochemical study with special emphasis on the pathogenetical distinction between soft tissue myoepithelioma and pleomorphic adenoma of the salivary gland. *Pathol Int* 62: 1-7.
33. Jo VY, Fletcher CD (2015) Myoepithelial neoplasms of soft tissue: an updated review of the clinicopathologic, immunophenotypic, and genetic features. *Head Neck Pathol* 9: 32-38.
34. Jo VY (2020) Soft Tissue Special Issue: Myoepithelial Neoplasms of Soft Tissue: An Updated Review with Emphasis on Diagnostic Considerations in the Head and Neck. *Head Neck Pathol* 14: 121-131.
35. Jo VY, Hornick JL, Antonescu CR, Patel RM (2020) Myoepithelioma, myoepithelial carcinoma, and mixed tumour. In: Antonescu CR, Blay JY, Bovée JVMG (eds) *Soft tissue and bone tumours. WHO Classification of Tumours*. 5th edition, Lyon: IARC 277-279.
36. Hornick JL (2019) *Practical Soft Tissue Pathology: A Diagnostic Approach*. 2nd edition, Philadelphia: Elsevier.
37. Bishop JA, Thompson LDR, Wakely PE, Weinreb I (2021) *Tumors of the Salivary Glands*. American Registry of Pathology.
38. Choi JH, Ro JY (2021) The 2020 WHO Classification of Tumors of Soft Tissue: Selected Changes and New Entities. *Adv Anat Pathol* 28: 44-58.
39. Hornick JL, Dal Cin P, Fletcher CD (2009) Loss of INI1 expression is characteristic of both conventional and proximal-type epithelioid sarcoma. *Am J Surg Pathol* 33: 542-550.
40. Le Loarer F, Zhang L, Fletcher CD, Ribeiro A, Singer S et al. (2014) Consistent SMARCB1 homozygous deletions in epithelioid sarcoma and in a subset of myoepithelial carcinomas can be reliably detected by FISH in archival material. *Genes Chromosomes Cancer* 53: 475-486.
41. Czader M, Eberhart CG, Bhatti N, Cummings C, Westra WH (2000) Metastasizing mixed tumor of the parotid: initial presentation as a solitary kidney tumor and ultimate carcinomatous transformation at the primary site. *Am J Surg Pathol* 24: 1159-1164.
42. Shimosawa H, Susa M, Honma T, Hiraishi E, Sakihara H (2009) Soft tissue mixed tumor of the hand. *Rare Tumors* 1: e30.