

A Radiographic Study of Pulp Crown Dimensions of the Mandibular Deciduous Second Molar

S Kazmi^{1,2*}, P Anderson¹, and HM Liversidge¹

¹Dental Physical Sciences Unit, Institute of Dentistry, Barts and The London, Queen Mary's School of Medicine and Dentistry, London, United Kingdom

²Riphah International University, I-14, Islamabad, Pakistan

*Corresponding author: Dr Shakeel Kazmi, Assistant Professor, Oral Biology Department, Islamic International Dental College, Riphah University, G-7/4, 7th Avenue, Islamabad Pakistan; Tel: 0092 333 5187232; Fax: 0092 51 2890690; E-mail: shakeel.kazmi@riphah.edu.pk

Received date: 14 Sep 2017; Accepted date: 22 Nov 2017; Published date: 28 Nov 2017.

Citation: Kazmi S, Anderson P, Liversidge HM (2017) A Radiographic Study of Pulp Crown Dimensions of the Mandibular Deciduous Second Molar. Int J Dent Oral Health 4(1): doi <http://dx.doi.org/10.16966/2378-7090.246>

Copyright: © 2017 Kazmi S, et al. This is an open-access article distributed under the terms of the Creative Commons Attribution License, which permits unrestricted use, distribution, and reproduction in any medium, provided the original author and source are credited.

Abstract

Aim: The aim of this study was to assess the difference in crown and pulp area and dimensions of the mandibular deciduous second molar in children using digitized images of bitewing radiographs and image J[®].

Materials and methods: Bitewing radiographs of 48 children (24 males and 24 females) aged 3.69 to 9.46 years were assessed in a retrospective cross sectional study. Bitewings were photographed and Image J[®] was used to measure crown and pulp area and some linear measurements. A t-test was used to compare the difference between mean dimensions in males and females.

Results: There were no statistically significant ($p < 0.05$) differences in the area (hard tissue with pulp and without pulp area) or in the horizontal (mesial distal crown width, pulp and crown width at cervix) or vertical (mesial and distal pulp horn height to occlusal surface) dimensions of this tooth between boys and girls.

Conclusions: There were no differences found in the area and linear measurements of the lower second molar between boys and girls.

Keywords: Bitewing radiographs; Crown; Pulp; Deciduous lower second molars; Image J[®]

Introduction

Dental pulp is integrally connected to dentine in terms of physiology and pathology, so anything that affects the pulp will affect the dentin. Both tissues embryonically share the same origin but despite this, these tissues are different in terms of conformation and structure. The pulp-dentine complex is now a widely acceptable term and dentine forms the main bulk of the tooth [1]. Enamel is the hardest material in all biological tissues, composing of organic and inorganic substances which cover the dentine [2]. The thickness of the hard tissue surrounding the pulp in the deciduous second molar varies from one individual to another [3].

The advantage of radiology is that it is non-destructive, and precise measurement can be obtained in order to study the dimensions of the dentin-pulp complex [4]. Following the discovery of X-rays in 1895, Raper introduced the bitewing radiograph technique in 1925 [5]. Since then radiology has been widely used for oral tissue diagnosis, age estimation, forensic dentistry as well as dental research [6,7]. Bitewings radiographs provide an excellent view of the pulp chamber but are limited as they show a two-dimensional projected images of three-dimensional object [8,9].

Although different parts of the body can be utilised for forensic identification, the tooth has the advantage of longevity in harsh environmental conditions [4]. Permanent dentition pulp is given much more importance than deciduous pulp in age determination, forensic and operative dentistry [3,10,11]. However a few studies describe deciduous tooth dimensions in terms of gender, ethnicity and pre and post-operative procedures [3,12]. Males have larger pulp and dentine dimensions compared to females in permanent teeth [13], but this pattern has not been consistently found in deciduous teeth [3,12]. Investigating the dentine

and pulp dimensions of the deciduous molars in males and females will contribute to our understanding of the effect of gender on tooth size. In addition, the measurements of dimensions of deciduous teeth are of interest as a possible method to determine the gender of juvenile skeletal remains. Therefore for the determination of gender identification, canines and molars can be used due to the late exfoliation age compared with incisors [12].

The aim of this study was to measure crown and pulpal linear and area dimensions in deciduous mandibular molars using bitewing radiographs, in order to investigate differences between boys and girls. Further changes in these measurements with age were also investigated.

Materials and Methods

Study design

The design of this study was a retrospective cross sectional study of archived bitewings radiographs of the Institute of Dentistry, Queen Mary University of London. All the radiographs used in this study were of dental patients and had been obtained for diagnostic purpose at the Institute of Dentistry, Queen Mary University of London. This research was carried out during March to September 2011.

Sample

The sample size included 48 children (24 males and 24 females) aged between 3.69 and 9.46 years of age (Table 1). The children were of mixed ethnic origin consisting of British Bangladeshi, Pakistani, Indian, and Caucasian. Radiographs were selected if they were of good quality (no overlapping of teeth) and the teeth were unrestored with no caries. Both right and left mandibular second molar selected.

Table 1: The frequency of age distribution by sex. 1 males 2 females

Age Categories		sex		Total
		1	2	
	2.01<4	1	3	4
	4.01<6	10	6	16
	6.01<8	9	12	21
	8.01<10	4	3	7
Total		24	24	48

Method of measurement

All measurements were carried out by the first author. The selected radiographs were photographed using a Canon Power Shot A3300 camera, tripod, and standard light box. The tripod and light box were set at a distance of 100 mm to photograph each radiograph. The images were analysed using image J (NIH, USA). The images were enlarged by 50% to fill the flat screen of a 19 inch computer monitor. The measurement scale was set and the actual width of the radiograph measured as 34 mm. After setting the scale, measurements were recorded in pixels. A pilot study was conducted to compare areas of the crown, measured from ten dots connected by lines or continuous outline.

Measurements of the area, linear and vertical dimensions were obtained by the first author (Figure 1). Area measurements:- Crown area was measured from the mesial dentine-enamel junction following the crown to the distal dentine-enamel following junction and connected by a straight line at the cervix level (Figure 1a). Pulp area was measured from the mesial cervix level following the outline of pulp to distal cervix level and joined by straight line (Figure 1b). Linear measurements:- Maximum bulbosity of the mesial and distal surface of the crown. Width of the pulp at the cervix level and width of the crown waist from one dentine-enamel junction to the other (Figure 1c). Vertical distances:- Distance from the tip of the distal and mesial pulp horn to the occlusal level (Figure 1d). An example of these measurements on a bitewing radiograph is illustrated in figure 2.

Intra –examiner reproducibility

Ten reference points were identified as illustrated in Figure 1e. These included area, linear and vertical measurements. Six radiographs were re-examined 2 weeks after examination by the first author and the results compared using a t-test. Analysis of results was carried out using PSAW 18 version (formerly SPSS Statistical, Statistical Package for the Social Sciences) and a comparison was carried out to assess which measurements were least variable (Table 2).

Statistical analysis

Descriptive statistics, including means, standard deviation, and standard error of mean of all area and linear data were calculated. A t-test was used to compare the means of all measurements between males and females. Statistical significance was determined at the level of 0.05 (Table 3).

Results

Table 4 shows the dental coronal pulp and hard tissue measurement from the 48 deciduous mandibular second molars studied. No statistically significant difference was observed in the width measurements of (such as mesio-distal crown width, pulp width at cervix, and crown width at cervix) between boys and girls. Further, there were no statistically differences in the height dimensions (such as mesial and distal pulp horn distance to occlusal surface of deciduous mandibular second molars) in the mesial pulp (p=0.72) and the distal pulp (p=0.45) dimensions between boys and girls. Similarly, no relationship with age was found in pulp area (p=0.06), hard tissue area (p=0.97) and the summation of pulp area and hard tissue area (p=0.96) (Table 4).

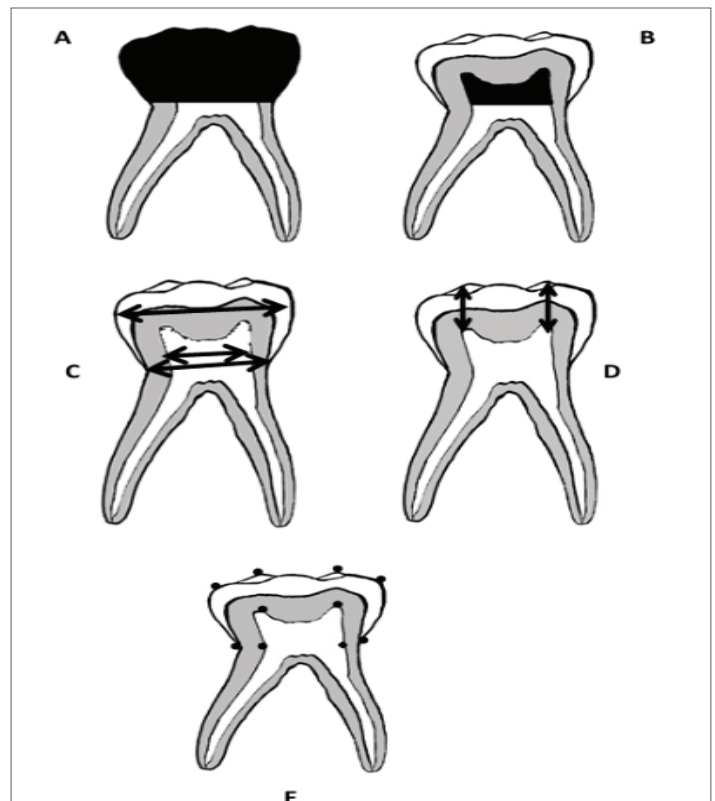


Figure 1: Tooth measurements of the deciduous second molar (A) black color area showing crown area from dentino enamel junction. (B) pulp area above dentinoenamel junction. (C) 1 and 2 distance from tip of distal and mesial pulp horns to the occlusal level. (D) 1 mesio-distal crown width, 2 crown width at cervix, 3 pulp width at cervix. (E) dots measurement method

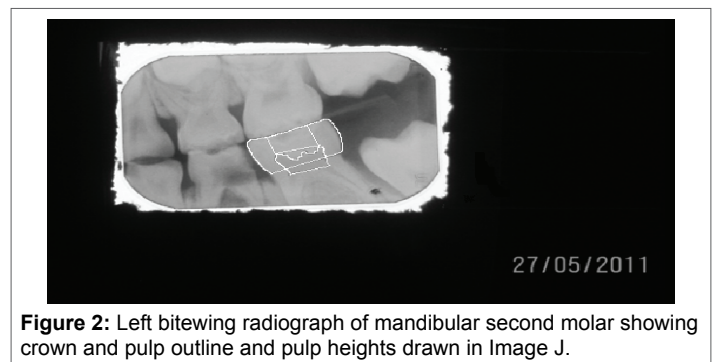


Figure 2: Left bitewing radiograph of mandibular second molar showing crown and pulp outline and pulp heights drawn in Image J.

Table 2: A comparison of results of the lines and points measurements. 1 line 2 points

Measurements	Mean	N=sample size	Standard deviation	Standard error
Pair 1 Crown area 1 (mm ²)	52.52	6	5.32	2.17
Crown area 2	50.20	6	2.09	0.85
Pair 2 pulp area 1 (mm ²)	10.20	6	1.4	0.57
pulp area 2	10.22	6	2.03	0.83
Pair 3 Distal pulp horn height 1 (mm)	3.60	6	0.63	0.26
Distal pulp horn height 2	3.81	6	0.55	0.22
Pair 4 Mesial pulp horn height 1 (mm)	3.40	6	0.39	0.16
Mesial pulp horn height 2	3.56	6	0.66	0.27
Pair 5 Inter pulpal distance 1 (mm)	5.03	6	0.32	0.13
Inter pulpal distance 2	4.79	6	0.22	0.09
Pair 6 Pulp width at cervix 1 (mm)	4.53	6	0.23	0.09
Pulp width at cervix 2	4.69	6	0.3	0.12

Table 3: Results of the mean difference between area measurements (intra observer reproducibility)

Pairs	Area in mm ² Height, distance and cervix in mm	Mean	Standard deviation	Standard error	lower	Upper	t	Degree of freedom	Sig (2-tailed)
Pair 1	Crown area 1 Crown area 2	2.32	4.52	1.85	-2.43	7.06	1.26	5	0.26
Pair 2	Pulp area 1 Pulp area 2	0.02	1.26	0.51	-1.34	1.3	-0.37	5	0.97
Pair 3	Distal pulp horn height 1 Distal pulp horn height 2	0.21	0.28	0.12	-0.51	0.08	-1.85	5	0.12
Pair 4	Mesial pulp horn height 1 Mesial pulp horn height 2	0.16	0.32	0.13	-0.51	0.18	-1.24	5	0.27
Pair 5	Inter pulpal distance 1 Inter pulpal distance 2	0.24	0.33	0.14	-0.11	0.59	1.78	5	0.14
Pair 6	Pulp width at cervix 1 Pulp width at cervix 2	0.16	0.2	0.83	-0.37	0.51	-1.95	5	0.11

Table 4: Results of the dimensions in males and females.

	Males			Females			P value
	Mean	SD	SE	Mean	SD	SE	
Mesial distal crown width	10.36	0.58	0.17	10.41	0.62	0.17	0.72
Pulp width at cervix	4.44	0.45	0.12	4.47	0.36	0.12	0.25
Crown width at cervix	8.46	0.45	0.14	8.52	0.5	0.14	0.67
Vertical Measurements (mm)							
Mesial pulp horn height to occlusal	3.87	0.5	0.1	3.87	0.11	0.11	0.72
Distal pulp horn height to occlusal	4.13	0.52	0.52	4.22	0.47	0.48	0.45
Area Measurements (mm) ²							
Hard tissue with pulp area	54.58	5.6	1.59	55.38	5.37	1.59	0.96
Pulp area	5.15	0.93	0.33	4.69	1.33	0.33	0.06

Discussion

Tooth dimensions are not only important in archaeology and forensic odontology but also in operative and endodontic dentistry. Any differences found between sizes, shapes, type of tooth can be related to sample size, age of the subjects, ethnicity differences and to radiographic errors [3,14]. The present study showed no statistically significant differences in horizontal and vertical linear measurements, as well as area measurements of mandibular second molar between girls and boys in this small sample aged between 3.69 and 9.46 year.

In terms of the mesio-distal crown width of deciduous second molars no significant difference was found among males and females in this study. In contrast to findings reported by Zilberman [15] and other studies [3,12]. This might be due to the small sample size or to the mixed ethnic groups made up of British Bangladeshi, Pakistani, Indian and Caucasian children in London.

No significant difference was found while comparing males and females in terms of pulp width and crown width at cervix in this study in agreement with findings by Arpana [3]. Vertical linear measurements such as mesial and distal pulp horn distance to occlusal surface between males and females showed no significant difference in this study.

Similarly the crown and pulpal areas measured in the present study also showed no significant difference found between males and females, similar to that reported in the Arpana study [3]. However there was no trend of pulp decrease seen with age observed in this study. The strength of our study was a reliable quantitative method on conventional bitewing radiographs. This was cross sectional study, a limitation of our study as other studies [16,17], as only a longitudinal study will assess the individual pulp dimensions over time for any age change.

Other ways of assessing deciduous tooth dimensions include from the mouth and indirectly from plaster casts. The majority of the studies were based on indirect methods [3,16,17]. Hunter [18] showed that it is very difficult to use direct method for measuring the tooth dimensions due to anatomical factors. In terms of mesial distal measurements, Eswara [16] study of south Indian children found that deciduous tooth size in males was statistically different than females. Anderson [19] study of direct and indirect techniques on African American showed no statistically significant in tooth size observed among two techniques. The measurements of second molar performed on cast models by Bravo [17] on Spanish children showed no statistically significant differences between males and females.

In this study conventional radiology was used whereas Arpana [3] used the radiovisiographic images. However to our knowledge, the differences between conventional and radiovisiographic related to dimensions to vertical and horizontal dimensions and area measurements have not been assessed. The age of the subjects in this study were between 3 and 9, while Harris [12] study consisted of 3 to 6 age group and Arpana [3] used children between 4 and 7 years.

In conclusion this study has provided baseline data about the morphologic characteristics of mandibular second molar teeth showing no differences in these between girls and boys in the cohort age group studied.

Funding: None declared

Competing Interest: None declared

Acknowledgements: None declared

References

1. Mjör IA, Sveen OB, Heyeraas KJ (2001) Pulp-dentin biology in restorative dentistry. Part 1: normal structure and physiology. *Quintessence Int* 32: 427-446.
2. Cuy JL, Mann AB, Livi KJ, Teaford MF, Weihs TP (2002) Nanoindentation mapping of the mechanical properties of human molar tooth enamel. *Arch Oral Biol* 47: 281-291.
3. Arpana V, Prabhakar AR, Raju OS (2010) Coronal pulp dimensions in noncarious and restored deciduous second molars. A radiovisiographic study. *J Dent Child (Chic)* 77: 42-48.
4. Cameriere R, Ferrante L, Belcastro MG, Bonfiglioli B, Rastelli E, et al. (2007) Age estimation by pulp/tooth ratio in canines by mesial and vestibular peri-apical X-rays. *J Forensic Sci* 52: 1151-1155.
5. Frommer HH, Fortier P (1995) History of the American Academy of Oral and Maxillofacial Radiology. *Oral Surg Oral Med Oral Pathol Oral Radiol Endod* 80: 512-516.
6. Carvalho SPM, da Silva RHA, Lopes Júnior C, Peres AS (2009) Use of images for human identification in forensic dentistry. *Radiologia Brasileira* 36: 757-763.
7. Panchbhai AS (2011) Dental radiographic indicators, a key to age estimation. *Dentomaxillofac Radiol* 40: 199-212.
8. Chandler NP, Pitt Ford TR, Monteith BD (2003) Coronal pulp size in molars: a study of bitewing radiographs. *Int Endod J* 36: 757-763.
9. Degering CI (1968) Diagnostic value of supplemental bitewing radiographs. *Dent Radiogr Photogr* 41: 56-57.
10. Drusini AG, Toso O, Ranzato C (1997) The coronal pulp cavity index: a biomarker for age determination in human adults. *Am J Phys Anthropol* 103: 353-363.
11. Drusini AG (2008) The coronal pulp cavity index: A forensic tool for age determination in human adults. *Cuad med forense* 14: 235-249.
12. Harris EF, Hicks JD, Barcroft BD (2001) Tissue contributions to sex and race: differences in tooth crown size of deciduous molars. *Am J Phys Anthropol* 115: 223-237.
13. Stroud JL, Buschang PH, Goaz PW (1994) Sexual dimorphism in mesiodistal dentin and enamel thickness. *Dentomaxillofac Radiol* 23: 169-171.
14. Maber M, Liversidge HM, Hector MP (2006) Accuracy of age estimation of radiographic methods using developing teeth. *Forensic Sci Int* 159: S68-S73.
15. Zilberman U, Smith P, Alvesalo L (2000) Crown components of mandibular molar teeth in 45, X females (Turner syndrome). *Arch Oral Biol* 45: 217-225.
16. Eswara K, Avula JS, Mallela GM, Enuganti S, Margana JSP, et al. (2014) Deciduous molar sizes and sexual dimorphism: South Indian study. *Journal of Pediatric Dentistry* 2: 13-19.
17. Bravo N, Facal M, Maroto M, Barberia E (2010) Relationship between mesiodistal crown diameters of permanent first molars and deciduous second molars. *Eur J Paediatr Dent* 11: 115-121.
18. Hunter WS, Priest WR (1960) Errors and discrepancies in measurement of tooth size. *J Dent Res* 39: 405-414.
19. Anderson AA (2005) Dentition and occlusion development in African American children: mesiodistal crown diameters and tooth-size ratios of primary teeth. *Pediatr Dent* 27: 121-128.